

## INDEX

---

<b>Sr no</b>	<b>TITLE</b>	<b>PAGE NO</b>
<b>1.</b>	<b>INTRODUCTION</b>	<b>1</b>
<b>2.</b>	<b>DRUG PROFILE</b>	<b>24</b>
<b>3.</b>	<b>LITERATURE SURVEY</b>	<b>33</b>
<b>4.</b>	<b>AIM AND OBJECTIVE</b>	<b>42</b>
<b>5.</b>	<b>PLAN OF WORK</b>	<b>43</b>
<b>6.</b>	<b>MATERIAL AND METHOD</b>	<b>44</b>
<b>7.</b>	<b>RESULT</b>	<b>57</b>
<b>8.</b>	<b>DISCUSSION</b>	<b>65</b>
<b>9.</b>	<b>CONCLUSION</b>	<b>67</b>
<b>10.</b>	<b>REFERENCE</b>	<b>68</b>

# Content

---

INDEX.....	I
LIST OF ABBREVIATION.....	II
CONTENTS .....	IV
LIST OF TABLES.....	VII
LIST OF FIGURES.....	VIII
<b>INTRODUCTION.....</b>	<b>1</b>
1.1 LIVER.....	1
1.1.1 Peritoneal Attachment.....	1
1.1.2 Anatomical Subdivision .....	2
1.1.3 Histology of Liver.....	5
1.1.4 Cells present in Liver.....	8
1.1.5 Functions of liver.....	10
1.1.6 The immunological functions of Liver.....	15
1.2 LIVER CIRRHOSIS.....	17
1.2.1 general consideration.....	17
1.2.2 Etiolgy of Liver Cirrhosis.....	18
1.2.3 Symptoms.....	20
1.2.4 Complication.....	20
1.2.5 Daignosis.....	22
<b>2. DRUG PROFILE.....</b>	<b>23</b>
2.1 GeneralconsiderationofGomutraArk.....	23

# Content

---

2.2 Properties.....	25
2.3 Chemical Component of Cow Urine.....	26
2.4. mythological Belief about Cow Urine .....	27
2.5 uses of Cow Urine.....	27
2.6 Mechanism of Action of Cow Urin.....	30
<b>3. LITERATURE SURVEY.....</b>	<b>32</b>
<b>4. AIM AND OBJECTIVE.....</b>	<b>41</b>
4.1 Aim of the study.....	41
4.2 Objectives of the study.....	41
<b>5. PLAN OF WORK.....</b>	<b>42</b>
<b>6. MATERIALS AND METHOD.....</b>	<b>43</b>
6.1 materials.....	43
6.1.1 Collection and Authentification of Drug .....	43
6.1.2 Chemicals and reagent.....	43
6.1.3 Instrumenrts and Equipments.....	43
6.1.4 Experimental animals.....	44
6.2 determination of hepatoprotective activity.....	44
6.2.1 Experimental Design.....	45
6.2.2 Dose Calculation.....	46
6.3 Evaluation of Hepatoprotective Activity.....	47
6.3.1 Estimation of biochemical parameters.....	47

## Content

---

6.3.2 Estimation of histopathological parameters.....	54
6.4 Statistical Analysis.....	55
<b>7. RESULTS.....</b>	<b>56</b>
7.1 Biochemical Analysis.....	56
7.1.1 Pre-treatment.....	56
7.1.2 Post- treatment .....	58
7.2 Histopathology study.....	60
<b>8. DISCUSSION.....</b>	<b>64</b>
<b>9. CONCLUSION.....</b>	<b>66</b>
<b>10. REFERENCES.....</b>	<b>67</b>

<b>Sr no</b>	<b>figure no.</b>	<b>Title of figure</b>	<b>Page no</b>
1	1	The bed of liver. The outline of the liver in shaded green. The central area is unshaded	1
2	2	The surface feature, ligaments and peritoneal attachments of the liver.	2
3	3	Cross-section of the structure at the portal hepatitis	3
4	4	The portal traid entering the hilum of the liver	3
5	5	The segmental anatomy of the liver with the tributaries of the portal vein	4
6	6	The hepatic vein	5
7	7	Cellular architecture of the liver. (A) The schematic shows an adult liver (red), with the gall bladder and extra hepatic ducts (green), in relation to the stomach and intestine (yellow). (B) A schematic of the cellular architecture of the liver showing the hepatocytes (pink) bile ducts (green), which run parallel to portal veins (blue) and hepatic arteries (red) to form the “portal triad”.	6
8	8	Diagram Showing Liver Lobules	6
9	9	Diagram Showing Liver Lobules	7
10	10	Diagram showing main cell types of Liver - hepatocytes, endothelial cells, Kupffer cells and Stellate cells.	8
11	11	benefits of cowurine from ancient text	24
12	12	benefits of cowurine from ancient text	24
13	13	Centrifugation apparatus	48
14	14	Autoanalyser for biochemical analysis	49
15	15	Test tube according to groups for biochemical analysis	49
16	16	SGOT level when inducing agent CCl <sub>4</sub> was given to	57

## List of figure

		every group	
17	17	SGPT level when inducing agent CCl <sub>4</sub> was given to every group	58
18	18	ALP level when inducing agent CCl <sub>4</sub> was given to every group	58
19	19	SGOT level when drug was given to standard , test 1 and test 2 group	59
20	20	SGPT level when drug was given to standard , test 1 and test 2 group	60
21	21	ALP level when drug was given to standard , test 1 and test 2 group	60
22	22	Histopathology of normal liver group	61
23	23	Histopathology of inducing liver group	62
24	24	Histopathology of standard iver group	63
25	25	Histopathology of test group 1 liver group	63
26	26	Histopathology of test group 2 liver group	64

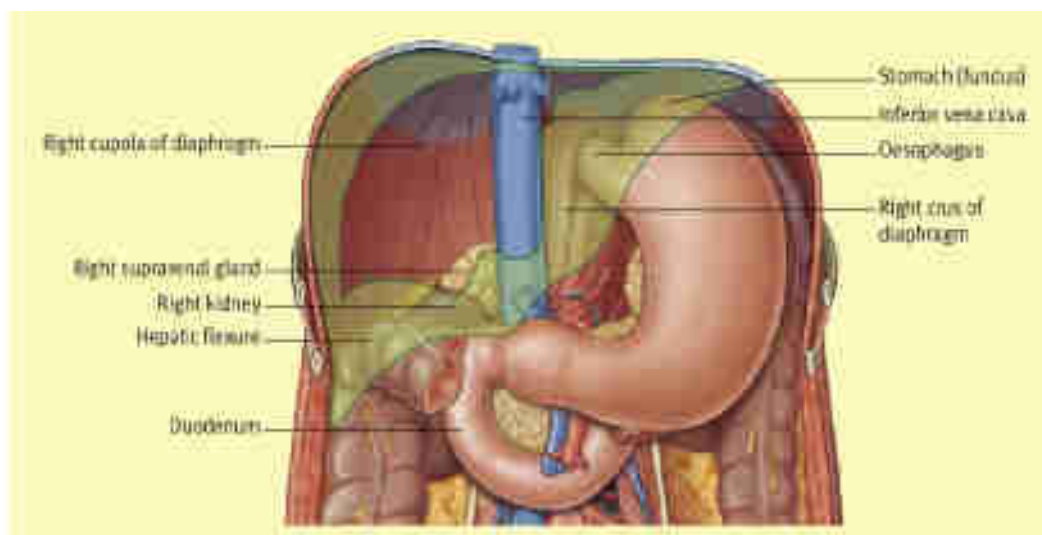
List of table

Sr. no	Table. No.	Title of table	Page no.
1	1	Summary of major function of Liver	11
2	2	Properties and use of Gomutra(Cow urine) according to Ayurveda	26
3	3	Chemical constituents of Healthy cow urine	27
4	4	Treatment protocol for all group	46
5	5	Reagent (1 and 2) composition at pH 8.0±0.1 at 25°C(SGOT)	50
6	6	Working reagent and sample to be taken in ml into pipette	51
7	7	Reagent composition (ALP)	54
8	8	In blank, sample and reagent in ml	54
9	9	Effect of carbon tetrachloride on liver enzyme marker	57
10	10	Effect of carbon tetrachloride on liver enzyme marker	59

## I] INTRODUCTION:

### 1.1 LIVER:

The liver is the largest organ in the body. Its domed upper surface relates entirely to the diaphragm while its postero-inferior, or visceral, surface rests against the abdominal oesophagus, stomach, upper duodenum, hepatic flexure of the colon, right kidney and suprarenal gland, as well as carrying the gall bladder (Figure 1).



**Figure 1.: The ‘bed’ of the liver. The outline of the liver is shaded green. The central bare area is unshaded<sup>[1]</sup>**

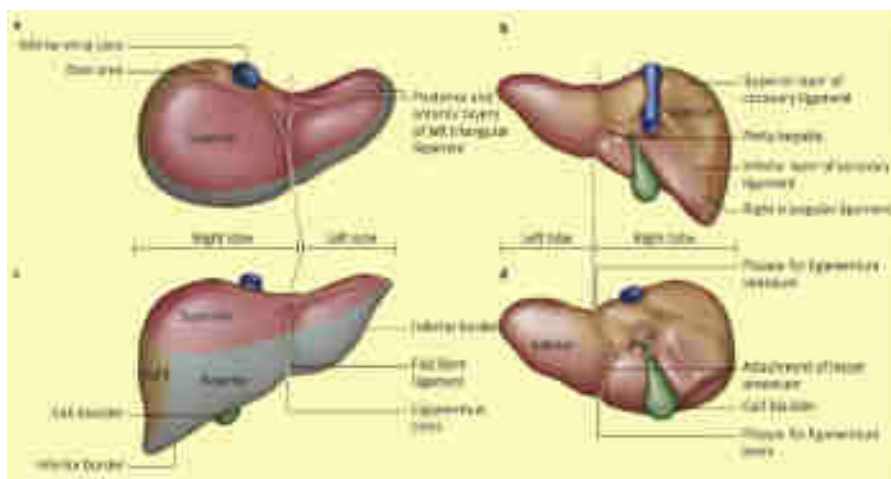
Its surface relations can be marked out by joining points on:

- \_ the right costal margin in the mid-axillary line, (the 10th rib)
- \_ the right 5th intercostal space ditto
- \_ the left 5th intercostal space in the mid-clavicular line.

The liver can be marked out on the subject by its dullness to percussion. Note that liver in the normal subject is not detectable on clinical examination; especially in a well developed male the contracted anterior abdominal muscles mimic the liver sides, but careful percussion reveals that the so called liver edge is similar!



### 1.1.1 PERITONIAL ATTACHMENT:



**Figure 2: The surface features, ligaments and peritoneal attachments of the liver.<sup>[1]</sup>**

Apart from a small posterior bare area, demarcated as the peritoneum from the diaphragm reflects onto it as the upper and lower layers of the coronary ligament, the liver is otherwise enclosed in peritoneum. To the right, these layers fuse to form the short right triangular ligament. The falciform ligament runs to the liver from the umbilicus carrying the ligamentum teres, in its free border. The ligamentum teres passes into its fissure on the inferior surface of the liver, while the falciform ligament passes over the dome of the liver and then divides its right limb joins the upper layer of the coronary ligament, while its left limb stretches out as the long narrow left triangular ligament, which joins the lesser omentum as this arises from the fissure for the ligamentum venosum. The lesser omentum arises from the fissures of the porta hepatis and the ligamentum venosum to attach along the lesser curvature of the stomach.

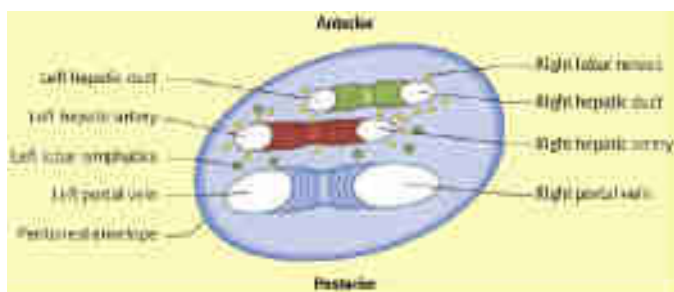
### 1.1.2.ANATOMICAL SUBDIVISION (Figure 2)

The superior aspect of the liver is divided by the falciform ligament into an anatomical right smaller left lobe. Posteroinferiorly, it bears an H-shaped arrangement of fossae:

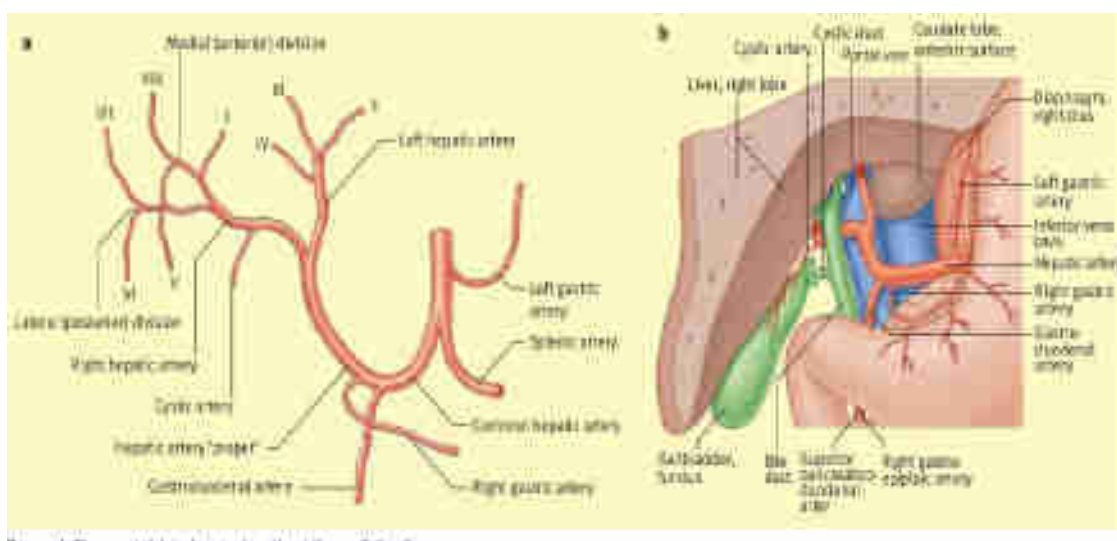
- a) Anteriorly and to the right is the fossa for the gall bladder.
- b) Posteriorly and to the right is the groove for the inferior vena cava.

c) Anteriorly and to the left is the groove for the ligamentum teres (often partially bridged by liver tissue). Posteriorly and to the left is the fissure for the ligamentum venosum. This represents the obliterated fetal ductus venosus, which shunts oxygenated blood from the umbilical vein to the inferior vena cava, short-circuiting the liver.

The cross-bar of the H is the porta hepatis. Two additional lobes are marked out on the visceral aspect of the liver between the limbs of the H is the quadrate lobe anteriorly and the caudate lobe behind.



**Figure 3: Cross-section of the structures at the porta hepatis.**



**Figure 4: The portal triad entering the hilum of the liver.**

These are:

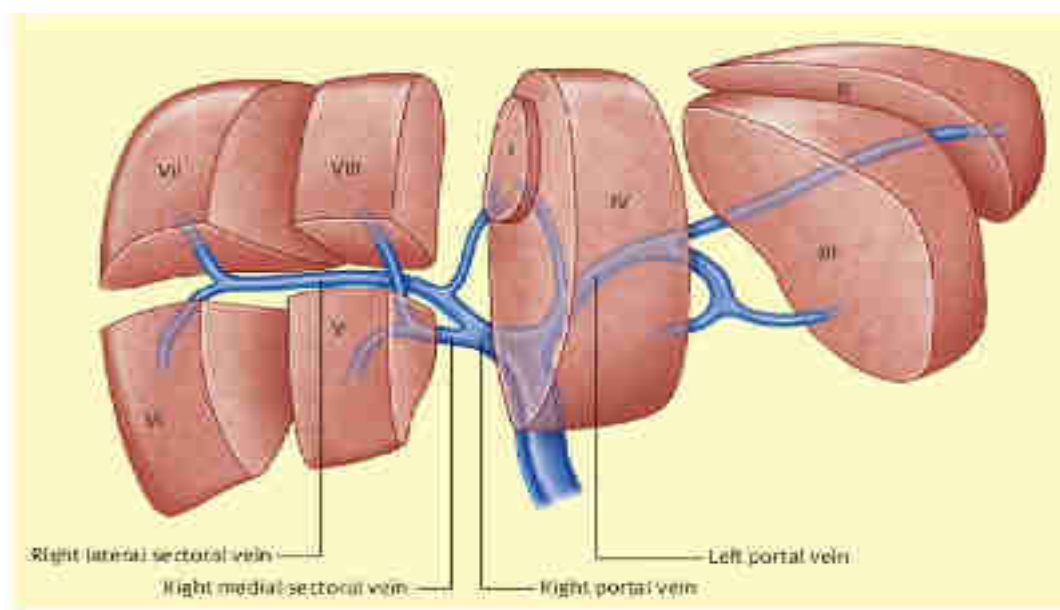
- 1) The right and left hepatic ducts, fusing into the common hepatic duct is anteriorly and to the right.
- 2) The hepatic artery dividing into its left and right branches rather more posteriorly and to the left.

3) The portal vein, dividing into its left and right branches posteriorly.

In addition to this portal triad, there are autonomic nerve (parasympathetic from the hepatic branch of the anterior vagus nerve, and sympathetic from the coeliac axis) and the portal lymph nodes.

#### a) Segmental anatomy:

The overall anatomical division of the liver into its right and left lobes is useful in gross description but is without morphological significance. The areas of supply of the right and left hepatic arteries, with accompanying portal vein and bile duct branches, can be demarcated by a line passing through the inferior vena cava and the fossa of the gall bladder, i.e. into roughly equal functional right and left lobes. These can be subdivided into a further eight segments, four to each functional lobe (Figure 5),



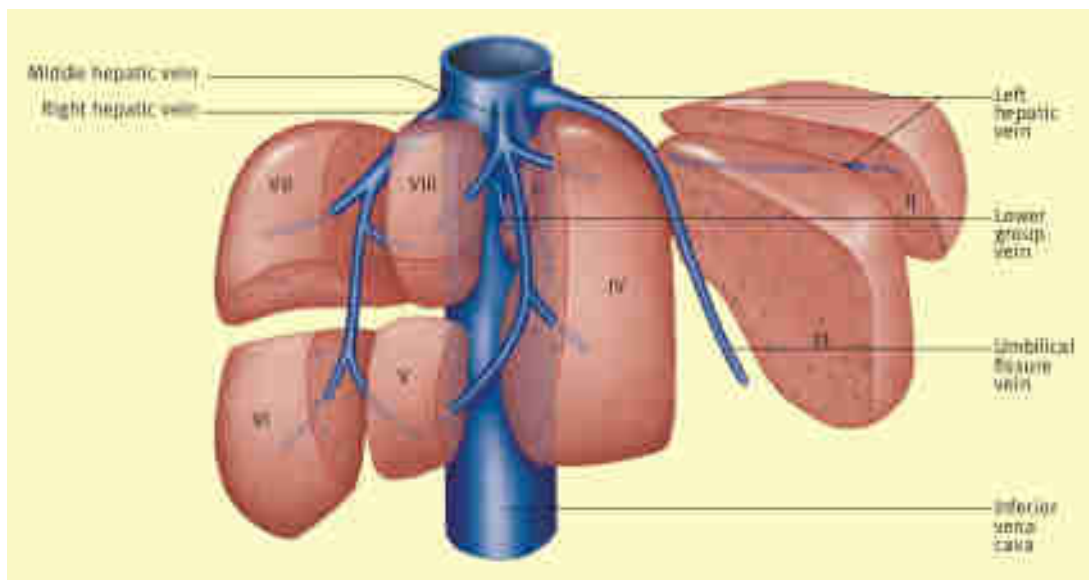
**Figure 5: The segmental anatomy of the liver with the tributaries of the portal vein.**

each segment with its individual blood supply and biliary drainage. This arrangement allows the surgeon to carry out segmental hepatic resections.

#### b) The hepatic veins: (Figure 6)

The portal venous blood returns to the inferior vena cava via the hepatic veins. These are large and have a different distribution to the portal triad. The three major veins are the right, left and central hepatic veins. These enter in a postero-superior direction through the liver substance to drain into the inferior vena cava at the postero-superior aspect of

the liver. The arrangement is variable, but usually the middle vein (the smallest of the three), opens into the left vein just before its termination. In addition, there is always a various number of accessory veins that run directly from the liver to open along the inferior vena cava distal to the openings of the main veins.



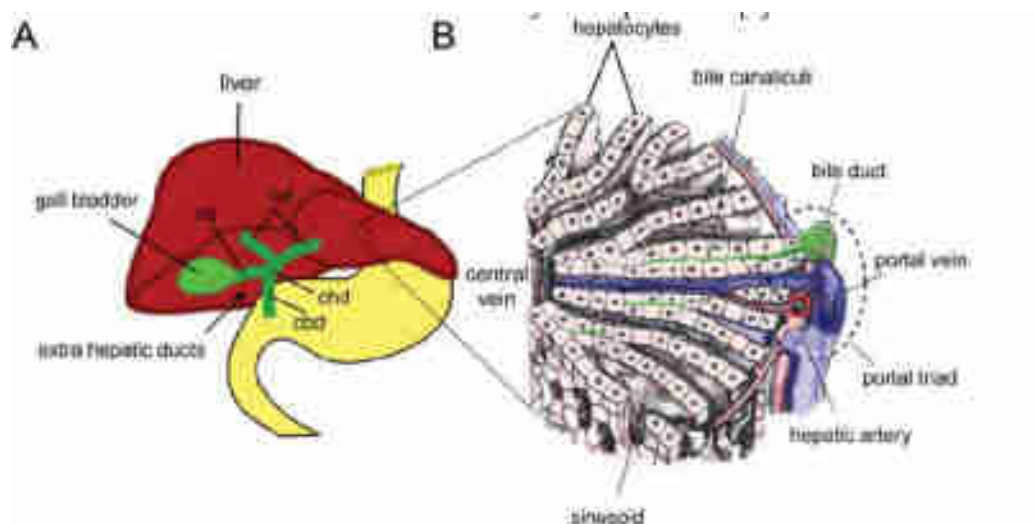
**Figure 6: The hepatic veins.**

Note that compression of the portal triad at the foramen of Winslow (Pringle's manoeuvre), will not control bleeding from divided hepatic veins in partial liver resections or in liver trauma.<sup>[1]</sup>

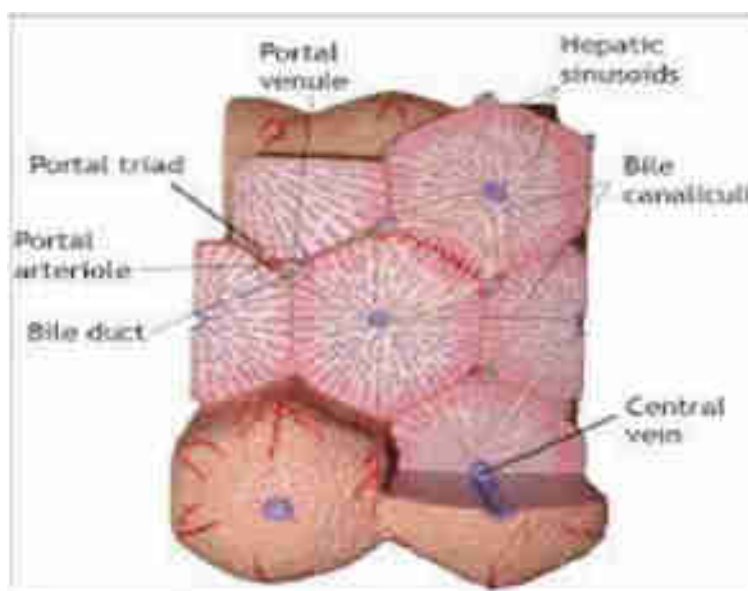
### 1.1.3 HISTOLOGY OF LIVER:

The basic functional unit of the liver is the liver lobule (Figure 7, Figure 8). A single lobule is about the size of a sesame seed and is roughly hexagonal in shape<sup>[2,3]</sup> explained that the primary structures found in a liver lobule include:

- Plates of hepatocytes which forms the bulk of the lobule
- Portal triads at each corner of hexagon
- Central vein
- Liver sinusoids that run from the central vein to the portal triads
- Hepatic macrophages (Kupffer cells)
- Bile canaliculi (—little canals) – formed between walls of adjacent hepatocytes



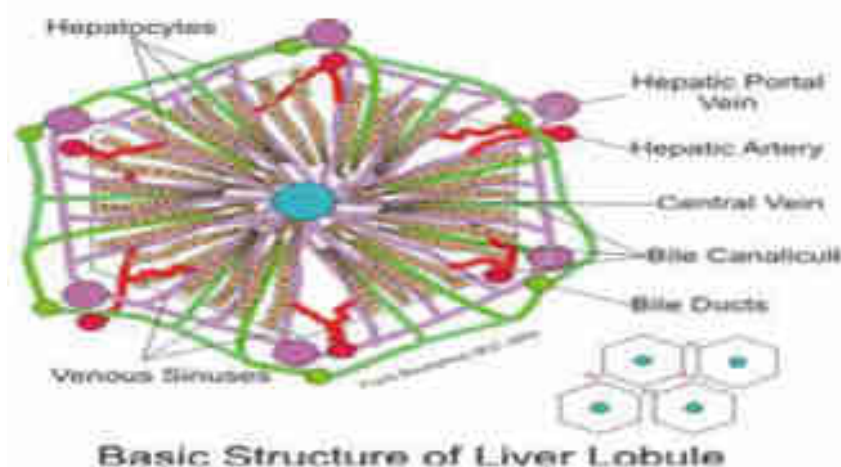
**Figure 7: Cellular architecture of the liver. (A)** The schematic shows an adult liver (red), with the gall bladder and extra hepatic ducts (green), in relation to the stomach and intestine (yellow). **(B)** A schematic of the cellular architecture of the liver showing the hepatocytes (pink) bile ducts (green), which run parallel to portal veins (blue) and hepatic arteries (red) to form the “portal triad”.



**Figure 8: Diagram Showing Liver Lobules**

The liver is the first site of passage for venous blood arriving from the intestines via vena porta <sup>[2,5]</sup>. The areas around the influx blood vessels are named periportal. The areas surrounding efflux blood vessels are the perivenous. The periportal area is highly

complex and consists of a dense matrix containing collagen where afferent blood vessels are found, together with bile ducts, nerve and lymph<sup>[2,5]</sup>. Spaces within the matrix contain a variable cell population, such as fibroblasts, hematopoietic cells and inflammatory cells. Also found here are epithelial cells of the bile ducts, endothelial cells of the blood vessels, and smooth muscles of arteries and veins<sup>[2,7]</sup>. The liver lobule consists mainly of plates of hepatocytes and sinusoids, with a light matrix of collagen to form a network between the two. Kupffer cells, as well as fat storing stellate cells.



**Figure 9: Diagram Showing Liver Lobules**

These types of cells reside mainly in the tissue space between the hepatocyte and the sinusoids. Terminal bile ductules connect here to the bile canaliculi between hepatocystic plates<sup>[2,7]</sup>. The walls of the hepatic sinusoid are lined by three different cell types: the sinusoidal endothelial cells, kupffer cells and stellate cells. Additionally, pit cells, the liver specific natural killer (NK) T cells are often present in the sinusoidal lumen<sup>[2,8]</sup>. The main parenchymal mass is normally that of hepatocytes. In rat, the hepatocytes make up about 60 % of liver cell count and the remaining 40 %, non-parenchymal cells only make up for about 6 -7 % of the liver volume while the remaining volume of approximately 23 % is formed by extracellular spaces<sup>[2,9]</sup>. The liver is made up of many different cell types. Four main cell types will be discussed for the purpose of this paper, namely:

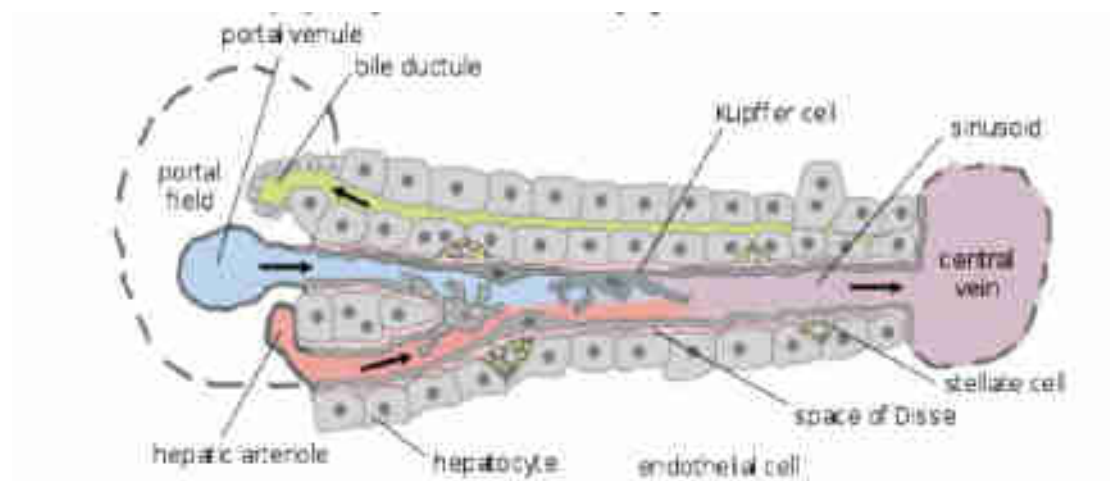
**a) Hepatocytes**

**b) Endothelial cells**



c) **Kupffer cells** (liver resident macrophages) and

d) **Stellate cells** (liver fat storing cells).



**Figure 10: Diagram showing main cell types of Liver - hepatocytes, endothelial cells, Kupffer cells and Stellate cells.**

e) **Space of Disse** – a small space between the sinusoids and the hepatocytes

The portal triads consist of three vessels: a hepatic portal arteriole, a hepatic portal venule, and a bile duct. The blood from the arteriole and the venule both flow in the same direction – through the sinusoids toward the central vein, which eventually leads to the hepatic vein and the inferior vena cava. Secreted bile flows in the opposite direction – through the bile canaliculi away from the central vein, toward the portal triad, and exiting via the bile duct. As blood flows through the sinusoids and the space of Disse toward the central vein, nutrients are processed and stored by the hepatocytes, and worn out blood cells and bacteria are engulfed by the Kupffer cells<sup>[2,3]</sup>.

#### 1.1.4 CELLS PRESENT IN LIVER:

##### 1) Hepatocyte:

Hepatocytes represent 60 % of the liver's cells and about 80 % of the liver's total cell mass. Most of the liver's synthetic and metabolic capabilities stem from the work of hepatocytes<sup>[2,3]</sup>. Hepatocytes are arranged in plates only a single cell thick<sup>[2,5]</sup>. (Figure 5) Blood flowing toward the hepatic vein within the space of Disse passes both exposed

surface areas of the hepatocyte plates and toxins and nutrients within the blood are extracted by the hepatocytes. Hepatocytes are large and rich in organelles such as endoplasmic reticulum and Golgi apparatuses. They contain many and large mitochondria, as well as lysosomes and peroxisomes <sup>[2,10]</sup>. The main function of hepatocytes is to participate in lipid, carbohydrate and protein metabolism. They also produce serum proteins such as albumin and coagulation factors<sup>[2,11]</sup>. Furthermore, hepatocytes produce and secrete bile as well as detoxify and excrete cholesterol, steroid hormones and xenobiotic drugs. Numerous xenobiotics are metabolized by the mixed-functions of monooxidases found in hepatocytes <sup>[2,12]</sup>. Structure and function of the hepatocytes within the liver lobule differs greatly depending on proximity to periportal or perivenous areas. Periportal type of hepatocytes are often smaller, but have larger mitochondria, and a larger Golgi apparatus as compared to the perivenous type. Perivenous hepatocytes on the other hand have larger endoplasmic reticulum. Functionally, periportal hepatocytes are more involved in gluconeogenesis, while perivenous are involved in glycolysis <sup>[2,6]</sup>. Additionally, perivenous hepatocytes are dominant with respect to P 450- dependent hydroxylation reactions <sup>[2,13]</sup> and glutamine synthetase<sup>[2,14]</sup>.

## **2) Endothelial Cells:**

The sinusoidal endothelial cells line the walls of the hepatic sinusoid and perform a function of filtration due to the presence of fenestrae<sup>[2,6]</sup>. (Figure 10) These cells also demonstrate large endocytic capacity for extracellular matrix components and immune complexes. In general they engulf smaller size particles and may play a role in clearance of viruses, but do not possess phagocytic function<sup>[2,15]</sup>. They may also function as antigen presenting cells and secrete certain cytokines and eicosanoids<sup>[2,8]</sup>.

## **3) Kupffer Cells:**

The liver harbors large amounts of kupffer cells, which represent the largest tissue resident macrophage population of the body<sup>[2,16]</sup>. (Figure 10). They are located within the sinusoid and are in constant contact with gut-derived particles that lead to low but constant amount of activation of these monocyte derived cells. Upon activation they are able to secrete a vast range of inflammatory mediators such as cytokines, reactive oxygen species, eicosanoids and nitric oxide<sup>[2,8]</sup>. Kupffer cells have receptors that enable them to



bind cells covered with immunoglobulins or bind to complement receptors and subsequently phagocytose cell<sup>[2,17]</sup>. Kupffer cells are even actively phagocytic *in vitro* and contain high levels of peroxidase, acid phosphatase and glucose 6-phosphate dehydrogenase<sup>[2,18]</sup>.

#### **4) Stellate Cells :**

The liver plays a central role in uptake and storage of vitamins A (Retinol) and stores about 95 % of retinoids found in the body. The fat storing perisinusoidal cells of the liver, stellate cells are the main vitamin A storing cells (Figure 10). They harbor large amounts of retinol and retinyl palmitate in lipid droplets within their cell cytoplasm<sup>[2,19]</sup>. They are located in the space of Disse (between hepatocytes and sinusoid) and generally protrude to come into contact with several sinusoids<sup>[2,19]</sup>. Additionally, they function to control the turnover of extracellular matrix and regulate sinusoid contractility. The stellate cells may become activated under stressful conditions and transformed into myofibroblast – like cells which play a key role in inflammatory fibrotic response<sup>[2,8]</sup>. When activated, stellate cells not only proliferate, but also produce increased amounts of extracellular matrix per cell. Transforming growth factor beta (TGF  $\beta$ ) is one of the most important signals to activate stellate cells, which leads to a higher transcriptional rate of mRNAs coding for extracellular matrix components such as collagen I, fibronectin and proteoglycans<sup>[2,6]</sup>. Lipid peroxidation products are also an important stimulus, whose effect may be augmented in oxidative stress conditions<sup>[2,20]</sup>.

### **1.1.5 FUNCTIONS OF THE LIVER:**

The liver has numerous functions best grouped into secretion of bile, metabolism of bilirubin, vascular and hematologic functions, metabolism of nutrients, metabolic detoxification and storage of minerals and vitamins

#### **1) Secretion of Bile:**

The liver assists intestinal digestion by secreting 700 to 1200 ml of bile per day. Bile is an alkaline, bitter-tasting, yellowish green fluid that contains bile salts (conjugated bile acids), cholesterol, bilirubin (a pigment), electrolytes and water. It is formed by hepatocytes and secreted into the canaliculi. Bile salts, which are conjugated bile acids,

**Table 1: Summary of major functions of Liver.****Table 1.** Summary Of Major Functions Of The Liver

Secretion of Bile
Metabolism of Bilirubin
Vascular and Hematologic Functions <ul style="list-style-type: none"> <li>➤ Important blood reservoir</li> </ul>
Metabolism of Nutrients <ul style="list-style-type: none"> <li>➤ Fat - fatty acid oxidation, synthesis of cholesterol/lipoproteins and production of ketoacids</li> <li>➤ Protein – Amino acid production, turnover of proteins</li> <li>➤ Carbohydrate – converts galactose/fructose to glucose, gluconeogenesis and contains 100g of glycogen for release</li> </ul>
Metabolic Detoxification <ul style="list-style-type: none"> <li>➤ Toxins</li> <li>➤ Hormones</li> <li>➤ Drugs</li> </ul>
Storage of Minerals and Vitamins <ul style="list-style-type: none"> <li>➤ Iron</li> <li>➤ Copper</li> <li>➤ Vitamins ADEKB<sub>12</sub></li> <li>➤ Glycogen</li> </ul>
Endocrine functions <ul style="list-style-type: none"> <li>➤ Activation of vitamin D</li> <li>➤ Conversion of thyroxine (T<sub>4</sub>) to T<sub>3</sub></li> <li>➤ secretes angiotensinogen</li> <li>➤ metabolises hormones</li> </ul>
Immunological/ Protective Functions
Reticuloendothelial Component <ul style="list-style-type: none"> <li>➤ Filters the portal blood from bacteria</li> <li>➤ Important in antigen presentation</li> <li>➤ Phagocytosis via kupffer cells</li> <li>➤ Removes haemolysis products</li> </ul>
Inactivation Of Toxins and Drugs <ul style="list-style-type: none"> <li>➤ Phase I (oxidation, reduction and hydrolysis)</li> <li>➤ Phase II (conjugation/ cytochrome P450 system)</li> </ul>

are required for the intestinal emulsification and absorption of fats. Having facilitated fat emulsification and absorption, most bile salts are actively absorbed in the terminal ileum and returned to the liver via the portal circulation for resecretion as follows:

1) Bile has two fractional components: the acid-dependent fraction and the acid-independent fraction. Hepatocytes secrete the bile acid-dependent fraction of the bile. This fraction consists of bile acids, cholesterol, lecithin (a phospholipid), and bilirubin (a bile pigment). The bile acid-independent fraction of the bile, which is secreted by the hepatocytes and epithelial cells of the bile canaliculi, is a bicarbonate-rich aqueous fluid that gives bile its alkaline pH.

2) Bile salts are conjugated in the liver from primary and secondary bile acids. The primary bile acids are cholic acid and chenodeoxycholic (chenic) acid. These acids are synthesized from cholesterol by the hepatocytes. The secondary bile acids are deoxycholic acid and lithocholic acid. These acids are formed in the small intestine by the action of intestinal bacteria, after which they are absorbed and flow to the liver.

- a) Both forms of bile acids are conjugated with amino acids in the liver to form bile salts
- b) Conjugation makes the bile acids more water soluble, thus restricting their diffusion from the duodenum and ileum.

## **2) Metabolism of Bilirubin:**

Bilirubin is a byproduct of destruction of aged red blood cells. It gives bile a greenish black color and produces the yellow tinge of jaundice.

1) Aged red blood cells are taken up and destroyed by macrophages of the mononuclear phagocyte system, primarily in the spleen and liver (in the liver these macrophages are Kupffer cells). Within these cells hemoglobin is separated into its component parts—heme and globin. The globin component is further degraded into its constituent amino acids, which are recycled to form of new protein. The heme moiety is converted to biliverdin by the enzymatic cleavage of iron. The iron attaches to transferrin in the plasma and can be stored in the liver or used by the bone marrow to make new red blood cells. The biliverdin is enzymatically converted to bilirubin in the macrophage of the mononuclear phagocytic system and then is released into the plasma. In the plasma, bilirubin binds to albumin and is known as unconjugated bilirubin or free bilirubin, which is lipid soluble.

2) In the liver, unconjugated bilirubin moves from plasma in the sinusoids into the hepatocyte. Within hepatocytes, it joins with glucuronic acid to form conjugated bilirubin, which is water soluble. Conjugation transforms bilirubin from a lipid-soluble substance that can cross biologic membranes to water-soluble substance that can be excreted in the bile. When conjugated bilirubin reaches the distal ileum and colon, it is deconjugated by bacteria and converted to urobilinogen. Most of the urobilinogen is then excreted in the urine, and a small amount is eliminated in feces.

**3) Vascular and Hematologic Functions:**

Because of its extensive vascular network, the liver can store a large volume of blood. The amount stored at any one duration depends on pressure relationships in the arteries and veins.

a) The liver can also release blood to maintain systemic circulatory volume in the event of hemorrhage.

b) Kupffer cells in the sinusoids of the liver remove bacteria and foreign particles from the portal blood. Because the liver receives all of the venous blood from the gut and pancreas, the Kupffer cells play an important role in destroying intestinal bacteria and preventing infections.

c) The liver also has hemostatic functions. It synthesizes prothrombin, fibrinogen, and clotting factors. Vitamin K, a fat-soluble vitamin, is essential for the synthesis of other clotting factors. Because bile salts are needed for reabsorption of fats, vitamin K absorption depends on adequate bile production in the liver.

**4) Metabolism of Nutrients :**

**a) Fats:** Fat is synthesized from carbohydrate and protein, primarily in the liver. Fat absorbed by lacteals in the intestinal villi enters the liver through the lymphatics, primarily as triglycerides. In the liver the triglycerides can be hydrolyzed to glycerol and free fatty acids and used to produce metabolic energy adenosine triphosphate (ATP), or they can be released into the bloodstream as lipoprotein. The lipoproteins are carried by the blood to adipose cells for storage. The liver also synthesizes phospholipids and cholesterol, which are needed for the hepatic production of bile salts, steroid hormones, components of plasma membranes and other special molecules.

**b) Proteins** - The plasma proteins, including albumins and globulins (excluding gamma-globulin), are synthesized by the liver. The liver also synthesizes several non essential amino acids and serum enzymes including aspartate aminotransferase, alanine aminotransferase, lactate dehydrogenase and alkaline phosphatase.

**c) Carbohydrates:** The liver contributes to the stability of blood glucose levels by releasing glucose during states of hypoglycemia (low blood sugar) and taking up glucose

during states of hyperglycemia (high blood sugar) and storing it as glycogen (glyconeogenesis) or converting it to fat. When all glycogen stores have been used, the liver can convert amino acids and glycerol to glucose.

#### **5) Metabolic Detoxification:**

The liver alters exogenous and endogenous chemicals (e.g. drugs), foreign molecules, and hormones to make them less toxic or less biologically active. This process, called metabolic detoxification, diminishes intestinal or renal tubular reabsorption of potentially toxic substances and facilitates their intestinal and renal excretion. In this way alcohol, barbiturates, amphetamines, steroids and hormones (including estrogens, aldosterone, antidiuretic hormone, and testosterone) are metabolized or detoxified, preventing excessive accumulation and adverse effects. Although metabolic detoxification is usually protective, in some durations the products of metabolic detoxification become toxins. Those of alcohol metabolism, for example, are acetaldehyde and hydrogen. Excessive intake of alcohol over a prolonged period causes these end products to damage the hepatocytes. Acetaldehyde damages cellular mitochondria, and the excess hydrogen promotes fat accumulation. This is how alcohol impairs the liver's ability to function.

The adult liver is the main organ responsible for detoxifying and metabolizing a variety of exogenous as well as endogenous compounds, rendering them more hydrophilic, which often affects their potency and level<sup>[2,6]</sup>. The enzymes responsible for the actions are primarily produced in hepatocytes and mainly divided into two groups phase I and phase II. The phase I enzymes are predominantly from the P- 450 family of genes, whose general function is to add polar groups, such as hydroxyl groups, to lipophilic molecules thus rendering them more hydrophilic<sup>[2,22]</sup>. The main function of the phase II enzymes is to covalently attach a water soluble moiety to the polar group added by the phase I enzymes. Usually such molecules are sugars or peptides, such as glucuronic acid or glutathione. This usually renders the compound less reactive. Examples of phase II enzymes are glutathione-S-transferase and UDP– glucuronosyl transferase. If the phase II reaction is impaired for some reasons or the phase I reaction is induced, this may leave the organism with an excess of reactive molecules from the phase I reaction, which can be detrimental. This can occur in the case of drug induced hepatotoxicity, when reactive

metabolites of the parent compound are formed, which subsequently negatively affects cellular functions<sup>[2,23]</sup>.

### **6) Storage of Minerals and Vitamins:**

The liver stores certain vitamins and minerals, including iron and copper, in durations of excessive intake and releases them in durations of need. The liver can store vitamins B12 and D for several months and vitamin A for several years. The liver also stores vitamins E and K. Iron is stored in the liver as ferritin, an iron-protein complex and is released as needed for red blood cell production.

### **1.1.6 THE IMMUNOLOGICAL FUNCTION OF LIVER:**

The liver is the main hematopoietic organ during certain stages in fetal development and continues to be a hematopoietic organ even after birth. It can produce all leukocytes lineages from resident hematopoietic stem cells<sup>[2,24,25]</sup>. The portal tract of the liver contains many different cells of hematopoietic origin, as well as hematopoietic stem cells<sup>[2,7]</sup>. The liver contains cells involved in adaptive and innate immunity.

#### **1) Innate Immunity of the Liver**

In comparison to other organs, the liver is particularly rich in cells of the innate immune system. The main cell types here are kupffer cells and NK T cells. NK T cells are not strictly part of innate immunity but functionally somewhere in between adaptive and innate. Of hepatic lymphocytes, approximately 30 % are NK cells, indicating the great contribution of NK cells to liver immunity. This may be compared to the approximately 15% that the two cell types combined contribute to in peripheral blood lymphocytes<sup>[2,26]</sup>. NK cells are one of the main producers of liver INF $\gamma$  in response to lipopolysaccharide (LPS), which partly depends on the activation of NK cells by IL-12 derived from activated Kupffer cells. They show high cytotoxic level towards tumor cells, with the help of the trail-ligand, which is up regulated by IL-2. Kupffer cells are derived from circulating monocytes and play a particularly important role in initiating inflammation in the liver. Kupffer cells differ in properties depending if they are periportal or perivenous. Periportal cells are larger and more active in phagocytosis, mirroring their function as the first line of defense of the body towards gut derived bacteria entering the blood stream and reaching the liver via the vena porta<sup>[2,27]</sup>. Perivenous kupffer cells on the other hand, are smaller and produce larger amounts of nitric oxide, as well as prostaglandins<sup>[2,28]</sup>. *Ex*

*in vivo* culture of kupffer cells have shown that the perivenous type secretes more than double the amount of TNF  $\alpha$  upon LPS stimulation. Kupffer cells are one of the main cell types to secrete cytokines, which then regulate the function not only of the kupffer cells themselves but also that of other cell types such as the NK cells. Stimulation of kupffer cells by bacteria and bacterial LPS leads to production of IL-12<sup>[2,29]</sup>, as well as TNF $\alpha$ . Other cytokines known to be produced by kupffer cells upon LPS stimulation include IL-6, TGF  $\beta$ , IL-1 $\beta$  and IL-8<sup>[2,30]</sup>. Cytokines derived from kupffer cells have in turn been proven to stimulate hepatocytes to further increase chemotactic response by secretion of IL-8<sup>[2,31]</sup>. Thus kupffer cells and NK cells hence mainly secrete Th1 type cytokines that activate the immune system. Immunosuppressive cytokines such as IL-10 may instead be secreted by stellate cells and regulatory T cells (but also by kupffer cells and NK cells)<sup>[2,32]</sup>.

## 2) Adaptive Immunity

Adaptive immunity can be classified into humoral immunity and cell-mediated immunity, mediated principally by B and T lymphocytes, respectively. T cells promote differentiation of B cells to antibody secreting plasma cells. T cells kill infected cells and secrete cytokines such as TNF  $\alpha$ , IFN  $\gamma$  and IL -6. TNF  $\alpha$  derived from kupffer cells play an important role in stimulating activation of T cells which then elicit a cytotoxic response<sup>[2,33]</sup>. Intrahepatic accumulation of highly activated CD8+ T cells is part of the pathogenesis process in hepatitis, including alcoholic hepatitis<sup>[2,34]</sup>. NK T cells constitute a distinct subpopulation of T cells that is particularly abundant in the liver, as previously mentioned. Infact, they are not strictly a part of adaptive immune response, but can be seen as having a function in between adaptive and innate immunity. These cells produce large amounts of the Th 2 cytokine IL-4<sup>[2,35]</sup> but also the Th1 cytokine IFN  $\gamma$ <sup>[2,36]</sup>. This ability of secreting both Th 1 and Th 2 type cytokines is particularly feature of NK cells. NK T cells are often present in the lumen of the sinusoid. They exhibit MHC-unrestricted killing of a variety of tumor cells, an level which is enhanced by IFN  $\gamma$ <sup>[2,8]</sup>. NK T cells have been shown to ‘crawl’ within the hepatic sinusoid, and stop upon T cell antigen receptor activation<sup>[2,37]</sup>. Naïve CD8+ T cells are also known to accumulate in the liver, where they may be activated, but at durations to a lesser degree than in lymph nodes. Thus, low-grade activation of T cells in liver rather leads to tolerance<sup>[2,38]</sup>. There is

also evidence for regulatory T cells expressing IL-10<sup>[2,32]</sup>. B cells have not been well studied in adult liver, however, there is a substantial B cell population showing similarities to splenic B cells. It has been shown that B cells play a role in liver fibrosis, as B cell deficient mice show significantly less fibrotic lesions after carbon tetrachloride induced liver injury. This effect is independent of antibody production. But also B cell antibody-dependent responses play a part in liver injury, as antibody production has been shown to be of importance in alcohol induced liver damage<sup>[2,39]</sup>.

## **1.2 LIVER CIRRHOSIS:**

### **1.2.1 GENERAL CONSIDERATION:**

Liver Cirrhosis is the common final pathway in most chronic liver diseases. In humans, it can occur as a result of liver damage due to viral, parasitic, toxic, metabolic or autoimmune disorders<sup>[40,41]</sup>. The pathogenesis of cirrhosis is only partly understood; therefore, models of Cirrhosis elucidate the mechanisms. Small rodents are preferred due to consideration of price and practicability as well as the availability of comprehensive genetic information. In the following , we will try to summarize important model of liver Fibrosis in mice.

The hallmark of liver fibrosis is an increase in the amount of extracellular matrix and a change in its composition, resulting in the deposition of collagen I in the space of Diss. In progressing fibrosis, the architecture of the liver is gradually disrupted. Destruction of the structure of the sinusoids impairs the function of the liver and eventually leads to cirrhosis<sup>[40,42]</sup> and its complications including portal hypertension and liver failure. This process affects not only hepatocytes, but also the non-parenchymal cells such as hepatic stellate cells and liver myofibroblasts<sup>[40,43,44]</sup>, which are essential for maintaining an intact liver structure and function<sup>[40,45]</sup>.

Cirrhosis is the part of general wound-healing response to liver damage of various origin and is defined by the accumulation and the qualitative changes in extracellular matrix (ECM) components. The hepatic stellate cell (HSC) is the main cellular effector of this phenomenon and the major producer of scar ECM<sup>[40,46,47]</sup>.



Probably the most important role in the injury response and fibrogenesis in the liver is played by a mesenchymal cell type known as the hepatic stellate cell<sup>[40,48-50]</sup>. These are cells formerly known as Ito cells or fat-storing cells. Resting hepatic stellate cells in the healthy liver store small droplets of vitamin A in their cytoplasm. Various stimuli, such as oxidative stress or cytokines, usually mediated directly or indirectly by cells of the immune system, can induce their transdifferentiation to an active fibrogenic cell type, marked by the disappearance of the vitamin A droplets, expression of  $\alpha$ -smooth muscle actin ( $\alpha$ -SMA)<sup>[40,51]</sup> and morphological changes of the cells. Activated hepatic stellate cells produce fibrotic components, mainly collagen type I<sup>[40,52]</sup>, proteoglycans, fibronectins<sup>[40,53]</sup>, hyaluronic acid<sup>[40,54]</sup>, inhibitors of matrix degradation such as the tissue inhibitor of metalloproteinase (TIMP) and a variety of cytokines and growth factors, among others TGF $\beta$ 1. Most facts gathered on this cell type have been established in rats – it is so far not fully clear how they can be translated to the mouse model. TGF- $\beta$ 1 plays a key role in the homeostasis of fibrogenic and fibrolytic processes. TGF- $\beta$  bound to its receptor induces phosphorylation of Smad2 or Smad3 proteins; phosphorylated Smad2 and Smad3 then recruit Smad4 to translocalize to the nucleus. Here, the Smad complex interferes with numerous transcription factors, thereby influencing the expression of collagens, TIMPs as well as matrix metalloproteinases (MMPs)<sup>[40,55-57]</sup>. The latter are important in the process of fibrolysis<sup>[40,58]</sup>. On the other hand, TIMP-1 is a major protein in the process of fibrogenesis; it prevents degradation of extracellular matrix. Its expression precedes the deposition of extracellular matrix in models of liver fibrosis<sup>[40,59]</sup> and is therefore assumed to be crucial for fibrogenesis.

### 1.2.1 ETIOLOGY OF LIVER CIRRHOSIS:

Cirrhosis has many causes. In the United States, chronic alcoholism and hepatitis C are the most common ones.

**1) Alcoholic liver disease.** To many people, cirrhosis of the liver is synonymous with chronic alcoholism, but in fact, alcoholism is only one of the causes. Alcoholic cirrhosis usually develops after more than a decade of heavy drinking. The amount of alcohol that can injure the liver varies greatly from person to person. In women, as few as two to three

drinks per day have been linked with cirrhosis and in men, as few as three to four drinks per day. Alcohol seems to injure the liver by blocking the normal metabolism of protein, fats, and carbohydrates.

**2) Chronic hepatitis C.** The hepatitis C virus ranks with alcohol as a major cause of chronic liver disease and cirrhosis in the United States. Infection with this virus causes inflammation of and low grade damage to the liver that over several decades can lead to cirrhosis.

**3) Chronic hepatitis B and D.** The hepatitis B virus is probably the most common cause of cirrhosis worldwide, but it is less common in the United States and the Western world. Hepatitis B, like hepatitis C, causes liver inflammation and injury that over several decades can lead to cirrhosis. Hepatitis D is another virus that infects the liver, but only in people who already have hepatitis B.

**4) Autoimmune hepatitis.** This disease appears to be caused by the immune system attacking the liver and causing inflammation, damage, and eventually scarring and cirrhosis.

**5) Inherited diseases.** Alpha-1 antitrypsin deficiency, hemochromatosis, Wilson disease, galactosemia, and glycogen storage diseases are among the inherited diseases that interfere with the way the liver produces, processes, and stores enzymes, proteins, metals, and other substances the body needs to function properly.

**6) Nonalcoholic steatohepatitis (NASH).** In NASH, fat builds up in the liver and eventually causes scar tissue. This type of hepatitis appears to be associated with diabetes, protein malnutrition, obesity, coronary artery disease, and treatment with corticosteroid medications.

**7) Blocked bile ducts.** When the ducts that carry bile out of the liver are blocked, bile backs up and damages liver tissue. In babies, blocked bile ducts are most commonly caused by biliary atresia, a disease in which the bile ducts are absent or injured. In adults, the most common cause is primary biliary cirrhosis, a disease in which the ducts become

inflamed, blocked, and scarred. Secondary biliary cirrhosis can happen after gallbladder surgery if the ducts are inadvertently tied off or injured.

**8) Drugs, toxins, and infections.** Severe reactions to prescription drugs, prolonged exposure to environmental toxins, the parasitic infection schistosomiasis, and repeated bouts of heart failure with liver congestion can all lead to cirrhosis.

### **1.2.3 SYMPTOMS:**

Many people with cirrhosis have no symptoms in the early stages of the disease. However, as scar tissue replaces healthy cells, liver function starts to fail and a person may experience one or more of the following symptoms:

- 1) exhaustion
- 2) fatigue
- 3) loss of appetite
- 4) nausea
- 5) weakness
- 6) weight loss
- 7) abdominal pain

8) spider-like blood vessels (spider angiomas) that develop on the skin As the disease progresses, complications may develop. In some people, these may be the first signs of the disease.

### **1.2.4 COMPLICATIONS:**

Loss of liver function affects the body in many ways. Following are the common problems, or complications, caused by cirrhosis.

**1) Edema and ascites.** When the liver loses its ability to make the protein albumin, water accumulates in the legs (edema) and abdomen (ascites).

**2) Bruising and bleeding.** When the liver slows or stops production of the proteins needed for blood clotting, a person will bruise or bleed easily. The palms of the hands may be reddish and blotchy with palmar erythema.

**3) Jaundice.** Jaundice is a yellowing of the skin and eyes that occurs when the diseased liver does not absorb enough bilirubin.

**4) Itching.** Bile products deposited in the skin may cause intense itching.

**5) Gallstones.** If cirrhosis prevents bile from reaching the gallbladder, gallstones may develop.

**6) Toxins in the blood or brain.** A damaged liver cannot remove toxins from the blood, causing them to accumulate in the blood and eventually the brain. There, toxins can dull mental functioning and cause personality changes, coma, and even death. Signs of the buildup of toxins in the brain include neglect of personal appearance, unresponsiveness, forgetfulness, trouble concentrating, or changes in sleep habits.

**7) Sensitivity to medication.** Cirrhosis slows the liver's ability to filter medications from the blood. Because the liver does not remove drugs from the blood at the usual rate, they act longer than expected and build up in the body. This causes a person to be more sensitive to medications and their side effects.

**8) Portal hypertension.** Normally, blood from the intestines and spleen is carried to the liver through the portal vein. But cirrhosis slows the normal flow of blood through the portal vein, which increases the pressure inside it. This condition is called portal hypertension.

**9) Varices.** When blood flow through the portal vein slows, blood from the intestines and spleen backs up into blood vessels in the stomach and esophagus. These blood vessels may become enlarged because they are not meant to carry this much blood. The enlarged blood vessels, called varices, have thin walls and carry high pressure, and thus are more

likely to burst. If they do burst, the result is a serious bleeding problem in the upper stomach or esophagus that requires immediate medical attention.

**10) Insulin resistance and type 2 diabetes.** Cirrhosis causes resistance to insulin. This hormone, produced by the pancreas, enables blood glucose to be used as energy by the cells of the body. If you have insulin resistance, your muscle, fat, and liver cells do not use insulin properly. The pancreas tries to keep up with the demand for insulin by producing more. Eventually, the pancreas cannot keep up with the body's need for insulin, and type 2 diabetes develops as excess glucose builds up in the bloodstream.

**11) Liver cancer.** Hepatocellular carcinoma, a type of liver cancer commonly caused by cirrhosis, starts in the liver tissue itself. It has a high mortality rate.

### **1.2.5 DIAGNOSIS:**

The doctor may diagnose cirrhosis on the basis of symptoms, laboratory tests, the medical history, and a physical examination. For example, during a physical examination, the doctor may notice that the liver feels harder or larger than usual and order blood tests that can show whether liver disease is present.

If looking at the liver is necessary to check for signs of disease, the doctor might order a computerized axial tomography (CAT) scan, ultrasound, magnetic resonance imaging (MRI), or a scan of the liver using a radioisotope (a harmless radioactive substance that highlights the liver). Or the doctor might look at the liver using a laparoscope, an instrument that is inserted through the abdomen and relays pictures back to a computer screen

A liver biopsy will confirm the diagnosis. For a biopsy, the doctor uses a needle to take a tiny sample of liver tissue, then examines it under the microscope for scarring or other signs of disease

Liver damage from cirrhosis cannot be reversed, but treatment can stop or delay further progression and reduce complications. Treatment depends on the cause of cirrhosis and any complications a person is experiencing. For example, cirrhosis caused by alcohol

abuse is treated by abstaining from alcohol. Treatment for hepatitis-related cirrhosis involves medications used to treat the different types of hepatitis, such as interferon for viral hepatitis and corticosteroids for autoimmune hepatitis. Cirrhosis caused by Wilson disease, in which copper builds up in organs, is treated with medications to remove the copper. These are just a few examples— treatment for cirrhosis resulting from other diseases depends on the underlying cause. In all cases, regardless of the cause, following a healthy diet and avoiding alcohol are essential because the body needs all the nutrients it can get, and alcohol will only lead to more liver damage. Light physical activity can help stop or delay cirrhosis as well.

Treatment will also include remedies for complications. For example, for ascites and edema, the doctor may recommend a low-sodium diet or the use of diuretics, which are drugs that remove fluid from the body. Antibiotics will be prescribed for infections, and various medications can help with itching. Protein causes toxins to form in the digestive tract, so eating less protein will help decrease the buildup of toxins in the blood and brain. The doctor may also prescribe laxatives to help absorb the toxins and remove them from the intestines<sup>[40,60]</sup>.

## 2 DRUG PROFILE:

### 2.1 GENERAL CONSIDERATION OF GOMUTRA ARK:

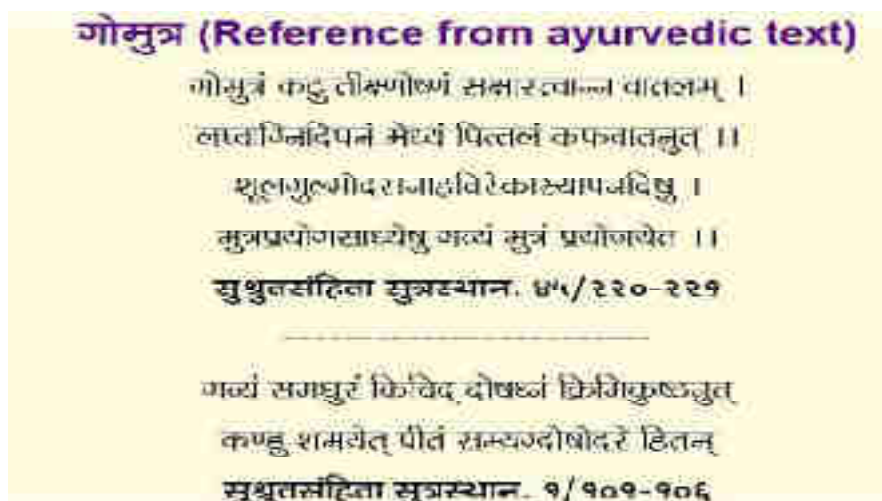


Fig 10: Benifits of Cow urine from ancient text<sup>[61]</sup>

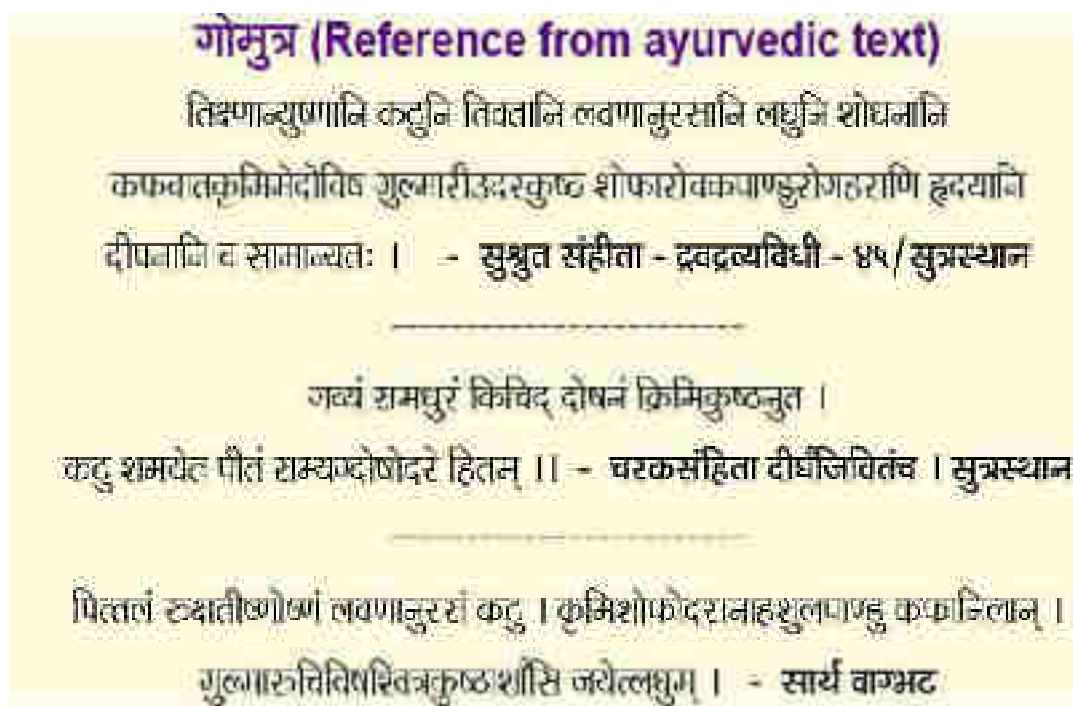


Fig 11: Benifits of Cow urine from ancient text<sup>[61]</sup>

Cow urine has a special significance Indian tradition. Cow urine is said to have a spiritual cleansing effect as well. Cow urine has been described as water of life or “Amrita” (beverages of immortality), the nectar of the God. “Panchagavya” is a combination of cow urine, milk, dung, ghee and curd. Indian cow breeds are unique and distinct species, popularly known as “kamdhenu” (one who can complete all wishes of mankind) and “gaumata”, (cow is called as mother). It has high socio-cultural values, plays significant role in rural economy, represent cattle wealth and bio-diversity. In Charaka Samhita, Sushruta Samhita and Vangbhat, described eight types of animal urines that can be used in medicine. Urine of cow is used in therapeutics. All these Mutras (eight type of urine from different animal) are sharp, hot, pungent, bitter with salty as secondary taste, light and promotive of evacuation. They relieve Kaphaja and vataja disorders, those caused by Krimi (worms), meda (excessive diposity), visha (poisoning), gulma (gaseous swelling of the abdomen), arsha (piles), skin diseases including leprosy, shopha (swelling), Agnimandya (loss of appetite), pallor, heart disease. They are dipaniya and panchaniya (digestive and carminative) in function<sup>[62,63]</sup>. The ancient Indian system of medicines values, panchgavya in the treatment of various human diseases<sup>[62,64]</sup>.

several curable and incurable diseases can be managed by use of cow urine as a medicine. The Ayurvedic classical texts, such as Charaka Samhita, bhavprakash and Shushrut Samhita, have described these indications for cow urine<sup>[62,65]</sup>. Though modern medicine has helped us to eradicate and cure several diseases of mankind and animals; but the existence of the incurable diseases like cancer, acquired immunodeficiency syndrome (AIDS), diabetes, rheumatoid arthritis, side effect of allopathy medicine, increasing trends of antibiotic resistance and chemical and biopesticides causing dietary risk has made the situation more critical than ever before. Thus it has become the matter of concern for the scientist and researcher to develop novel therapies<sup>[62,66]</sup>.

Cow urine contains nitrogen, sulphur, phosphate, sodium, manganese, iron, silicon, chlorine, magnesium, maleic, citric, tartaric and calcium salts, vitamin A, B, C, D, E, minirals, lactose, enzymes, creatinine, hormones and gold acids. Ingredients of cow urine are similar with human body. Hence consumption of cow urine is usefull to maintain the balance of these substances and cures incurable diseases<sup>[66,67]</sup>.



Medicinal properties of cow urine has been granted by US, as patent (No. 6,896,907 and 6,410,059); bioenhancer, antibiotic, antifungal and anticancer agent properties are particularly mentioned in those patents. Cow urine increases potency of “taxol” (paclitaxel) against MCF-7, a human breast cancer cell line, in *in vitro* assays (US patent No. 6,410,059)<sup>[66,68]</sup>

## 2.2 PROPERTIES:

**Table 2. : Properties and use of Gomutra (Cow urine) according to Ayurveda**

Acharya	Qualities	Effect of Doshas	Other effect on body
Charka	Sweet	Decrease Vata, pitta and kapha	Wormicide, use in various skin disorders, beneficial in leprosy, itching and ascites.
Shushruta sutra	Pungent, sharp, hot, light, alkaline	Decrease Vata and kapha	Promotes intellect and digestive power, beneficial in colic, digestive disorder, constipation, useful as purgative and for non lubricant enema

**Some important formulations in which gomutra is used<sup>[62,73]</sup>:**

1. Ashwinikumarras
2. Arshakutharrasa
3. Sanjivani vati
4. Mandurvatak
5. Punarnavamandur
6. Panchamrutlohamandur

7. Tryushanadimandur
8. Agnimukhmandur
9. Panchagavyaghrita
10. Kasisadi Taila

### 2.3 CHEMICAL COMPONENT OF COW URINE <sup>[62,74]</sup>:

Water- 95%

Urea- 2.5%

Minerals, salt, Hormones, Enzyme- 2.5%

Healthy cow urine has volume of 17-45ml/kg/day with specific gravity ranging from 1.025-1.045. Its pH ranges between 7.4 to 8.4 with seasonal variations. Urea nitrogen and total nitrogen varies between 23-28 ml/kg/day and 40-45 ml/kg/day respectively. Other important constituents are given in table below.

**Table 3.: Chemical constituents of Healthy cow urine**

Ammonium nitrogen	1-1.7 ml/kg/day
Allontoin	20-60 ml/kg/day
Calcium	0.1-1.4 ml/kg/day
Chloride	0.1-1.1 mmole/kg/day
Creatinine	15-20 ml/kg/day
Magnesium	3.7 ml/kg/day
Potassium	0.08-0.15 mmol/kg/day
Sodium	0.2-1.1 mmol/kg/day
Sulphate	3-5 mg/kg/day
Uric acid	1-4 mg/kg/day
Leucocyte	<15 micron It

## 2.4 MYTHOLOGICAL BELIEF ABOUT GOMUTRA ARK:

Lord *Shiva* narrated “Benefits of Urine Therapy” to Mother *Parvati* which has been referred in the ancient book “*Dammar Tantra*” in Vedas. In ancient books urine is referred as “*Shivambu*” (Auto urine) meaning water of *Shiva*.

Therapy of urine is the ancient method of treatment. The powerful practice of healing “Self-urine therapy” has been referred in “*Shivambukalpa Vidhi*” part of 5000 years old document called *Dammar Tantra* linking this practice to Vedas the sacred Hindu texts. Reference of urine therapy is also found in almost all the volume of *Ayurvedic literature* and in one of the volume of *Bhavaprakasha* urine is termed as “*Vishaghna*” (Anti Poisonous) killer of all poisons and “*Rasayan*” (*Rejuvenative*) which can rejuvenate even old person and purify blood and cures all skin diseases.<sup>[62,69]</sup>

Cow urine destroys the diseases that are caused by poison (Toxin). Various poisonous chemicals can be purified with the help of cow urine. Cow urine increases the immunity power by increasing resistance power against diseases in human body.<sup>[62,70]</sup>

## 2.5 USES OF COW URINE:

**A) Antidaibetic property:** There are various ways to developed resistant against antimicrobial drugs. Recently the use of antibiotics has been increased tremendously. There are so many drugs which found ineffective against various bacteria and viruses. Vancomycin resistant *Enterococcus*, and ciprofloxacin resistance *P. aeruginosa* are some of the examples. Different study has been shown that CU (Cow Urine) is much effective against the drugs resistant bacteria and viruses. Minimum inhibitory concentration (MIC) values for Cow urine extract of *A. indica* was 12.68 mm (*E. Coli*), 9 mm (*K. pneumonia*) and along with this there is >8.66 mm zone of inhibition for MDR *S. aureus*, *P. aeruginosa* and *P. vulgaris*.<sup>[62,789,80]</sup>

### **B) Fungicide and Biofungicide**

Various experiments show fungicidal effect against various species of *C. tropicalis*, *Aspergillus Malassezia*, and *C. glabrata*. CU inhibit the growth of *Malassezia* fungi (90-95%) which is responsible for causing dandruff for a longer time (4-5 days). Also CU shows significant effect in various microorganisms which is responsible different

diseases in crops. Study found that Lemon Juice extract and Neem leaves extract less effective than CU.<sup>[62,81]</sup> CUC (cow urine concoction) 5% showed maximum antifungal activity against *A. niger* (93%), *A. oryzae* (92.67%) and *A. flavus*(83%)..<sup>[62,82]</sup>

### **C) Antiseptic**

Cow urine shows significant effect in wound healing activity in Wistar albino rats. Study found that CU urine heal wound faster 1% w/w nitrofurazone ointment locally. <sup>[62,83]</sup>

### **D)Anthelmintic Activity**

CUC was better than piperazine citrate as anthelmintic agent at both 1% and 5% concentrations. <sup>[62,84]</sup>

### **E)Bioenhancer**

A ‘bioenhancer’/‘biopotentiator’ is substances that increase the bioavailability and bio-efficacy of active substance with which they are combined without having any activity of their own at the dose used. *Ayurveda*, has mentioned ‘*yogvahi*’ principle to describe the bioenhancing properties of medicines. It increases the oral bioavailability, results in lowering their dose and side effects. By integrating Ayurvedic science with modern methods of research, we can develop more viable drug formulations<sup>[62,85]</sup> CU which can be used as bioenhancer in antifungal, antimicrobial, and anticancer agents. <sup>[62,86]</sup> In *Ayurveda Rasayana* medicine have properties to increase body immune system thus CU contains the similar *Rasayana tatva* and also serves as bioenhancer 2<sup>[62,87]</sup>CUD (Cow urine Distillate) is more effective bioenhancer than CU. CUD increase the transport of antibiotics by 2-7 folds like tetracycline, rifampicin, and ampicillin across the intestinal wall<sup>[62,88]</sup>. It also enhances the potency of taxol against MCF-7 cell lines. It increases the bioavailability of rifampicin by 80-fold in 0.05 microgm/ml concentrations and clotrimazole by 5 fold in 0.88  $\mu$  g/ml concentration. The activity of rifampicin increases by about 5-7 folds against *E. coli* and 3-11 folds against Gram-positive bacteria, when used along with CU <sup>[62,84]</sup>. Potency of paclitaxel has been observed to increase against MCF-7, a human breast cancer cell line in *in-vitro* assays. The bio-enhancing ability of CU is by providing the absorption of drugs across the cell membrane. US Patent is also granted for bioenhancer along with antibiotics, antifungal and anticancer activity (6896907,6410059) of CU.

Various properties and activity of CU has been applied and widely used in many *ayurvedic* formulations. *Panchagavyaghrita*, *Lashunadhghrita*, *Sidhartakghrita* are used for psychiatric illness and abdominal tumor. Other formulations like *Mandurvatak*, *Darvighrita*, and *Punnarvamandur* also contains Cow Urine. CU is used as adjuvant along with *Hareetakyadiyog*, *Swarnkshiryadyog*, *Swarnmakshikbhasma*, *Gvakshyadichurana* and many other formulations. *Ghritas* (Medicated cow Ghee) are also available as semisolid preparations while *bhasms*, *yogs*, and *churans* are in the powder form.

### **F)Anticancer Properties**

CU has antioxidant properties and is a free radical and thus it neutralizes the oxidative stress. CU helps by repairing the damaged DNA and is therefore, effective as anti-cancer therapy. <sup>[62,89]</sup>

Chemopreventive potential of CU was observed in a study, which was conducted on 70 Swiss albino mice for 16 weeks. Papilloma were induced by 7, 12- dimethyl benzanthrane and later promoted by repeated application of croton oil. In mice treated with CU, the incidence of tumor (papilloma), tumor yield, and its burden was statistically less than the untreated group <sup>[62,90]</sup> Effect of Cow Urine on various types of cancers was studied by Jain and his coworkers. Decrease in severity of various clinical symptoms (pain, inflammation, burning sensation, difficulty in swallowing, and irritation) was reduced from day 1 to day 8 with CU therapy. Percentage of patients with severe symptoms decreased from 82.16 to 7.9 on day 8, patients with moderate symptoms increased from 15.8 to 55.3 and with mild symptoms, patients increased from 1.58 to 36.34. The severity of symptoms decreased further with continued CU therapy <sup>[62,91]</sup>

### **G) Immuno-stimulant**

The use of herbs and minerals (like *chavanprash* and *panchgavya*) for improving the resistance of the body against common infections and pathogens has been a principal of *Ayurveda*. Ancient Ayurvedic say that consuming CU daily increases the resistance to diseases by up to 104%. This has also shown enhancement in humoral, and cell-mediated immune response in mice <sup>[62,92]</sup>

### **H) Wound healing activity of cow urine in DM induced rats**

Study demonstrated that cow urine ark increases wound healing in diabetic wound patient. Thus, it helps in increases wound healing in diabetic patients because of its property of enhancing granulation tissue formation. <sup>[62,93]</sup>

#### **I) Anti-urolithiatic effect of cow urine :**

Cow urine ark showed significant effect against renal calculi and storing of compromised renal function. This type of action of CU might be due to it reduce excretion of CaO crystals and inhibit process of crystallization. Further experimental studies are needed to know its mechanism of action.

### **2.6 MECHANISM OF ACTION OF COW URINE:**

CU have different fractions like antimicrobial activity due to the presence of certain components like volatile and nonvolatile ones<sup>[62,94]</sup> Presence of creatinine, urea, *swarnkshar* (aurum hydroxie), phenols, carbolic acid, calcium, and manganese has explained the germicidal and antimicrobial properties of CU. Presence of amino acids and urinary peptides may enhance the bactericidal effect by increasing the bacterial cell surface hydrophobicity. CU enhances the phagocytosis activity of macrophages. fresh CU contain higher amounts of phenols than CU distillate (CUD) makes it more effective against microbes. After photo-activation, few biogenic volatile inorganic and organic compounds such as CO<sub>2</sub>, NH<sub>3</sub>, CH<sub>4</sub>, methanol, propanol and acetone, and some metabolic secondary nitrogenous products are also formed <sup>[62,95]</sup> Photo-activated CU (PhCU) is highly acidic than fresh CU this may be responsible for increase in bactericidal action. Inorganic substances in cow urine such as phosphorus, chloride and dimethylamine may also play an important role. CU prevents the development of antibacterial resistance by blocking the R-factor, a part of plasmid genome of bacteria CU contains phenolic acids (gallic, caffeic, ferulic, o-coumaric, cinnamic, and salicylic acids) which have antifungal characteristics <sup>[62,96]</sup>. Antioxidant property of uric acid and allantoin present in CU correlates with its anticancer effect. CU reduces apoptosis in lymphocytes and helps them to survive better This action may be due to the free radical scavenging activity of the urine components, and these components may prevent the process of aging. It efficiently repairs the damaged DNA. Daily consumption of CU improves immunity due to the presence of *swarnkshar* and fastens the wound healing

process, which is due to allantoin<sup>7</sup> CU enhances the immune-competence by improving the synthesis of interleukin-1 and -2, augments B - and T- lymphocyte blastogenesis, and IgA, IgM and IgG antibody titers <sup>37</sup> Early morning first voided CU is more sterile and have more macro and micronutrients and other enzyme/urea content could be more effective.

### 3] LITERATURE SURVEY:

#### 3.1 Carbon Tetrachloride Induced Liver Toxicity And Its Prevention By Various Herbal Drug:

- 1) **Z. Zhao, H. Yu, Y. Peng et al.:** reported that comparison of effect of Formulas clearing away heat and promoting blood circulation on prevention and treatment of liver fibrosis in CCl<sub>4</sub> induced mice was done using Herbal medicine Biejia Yinzi, Gexiazhuyu Tang, and Fugan Wan and was treated for 4 weeks. Gexiazhuyu Tang and Fugan Wan treatment improved inflammatory necrosis and Fat degeneration. Reduced collagen accumulation<sup>[98]</sup>.
- 2) **C. Luo, Z.-X. Chen, X.-H. Tan et al.:** It stated the therapeutic effect of Fuzhenghuayu decoction in a CCl<sub>4</sub>- induced liver cirrhosis rat model and on hepatic stellate cell activation. The study was carried out for 6 weeks, the herbal medicine taken was Fuzhenghuayu decoction. The pathological and biochemical findings were investigated such as Decreased ALT, AST, and Tbil. Reduced area ratio of liver fibrosis and  $\alpha$ -SMA<sup>[99]</sup>.
- 3) **L.J. Zhang, M. Y. Sun, B.B. Ning et al.:** reported that Xiayuxue decoction attenuated hepatic stellate cell activation and sinusoidal endothelium defenestration in CCl<sub>4</sub>- induced fibrotic liver of mice was studied. The study was carried out for 6 weeks, the herbal drug was Xiayuxue decoction. The pathological and biochemical findings were investigated such as Decreased Sirius red positive area. Reduced  $\alpha$ -SMA and type-I collagen<sup>[100]</sup>.
- 4) **X. Shen, S. Cheng, Y. Peng, H. Song, and H. Li.:** reported that Attenuation of early liver fibrosis by herbal compound “Diwu Yanggan” through modulating the balance between epithelial transition was studied. The study was carried out for 6 weeks and herbal drug was Diwu Yanggan. . The pathological and biochemical findings were investigated such as reduced ALT, AST, Hyp, and collagen deposition and tissue damage. Increased E-cadherine, TGF- $\beta$ ; reduced vimentin, BMP-7, Hh ligand Shh, receptor Smo and Ptc, and Gli1<sup>[101]</sup>.
- 5) **Y.-N. Zhou, M.-Y. Sun, Mu et al :** the study reported that Xuefuzhuyu decoction inhibition of angiogenesis attenuates liver fibrosis induced by CCl<sub>4</sub>. The study was carried out for 6 weeks and herbal drug was Xuefuzhuyu



decoction. The pathological and biochemical findings were investigated such as reduced ALT, AST, Tbil, and Hyp. No ECM deposition and reduced necroinflammatory foci. Decreased  $\alpha$ -SMA, collagen I, CD31, VEGF, VEGFR-2, HIF-1  $\alpha$ , and ADMA; increased Py-STAT<sup>[102]</sup>.

- 6) **X.X. Wu, L.-M. Wu, J. –J. Fan et al.:** reported that Cortex Dictanni extract induces apoptosis of activated hepatic stellate cells via STAT1 and attenuates liver fibrosis in mice. The study was carried out for 7 weeks and herbal drug was ethanolic extract of cortex Dictanni. The pathological and biochemical findings were investigated such as Improved pathological grading, reduced collagen deposition and Hyp content. Increased Py-STAT1<sup>[103]</sup>.
- 7) **H. Qiao, H. Han, D. Hong, Z. Ren, Y. Chen, and C. Zhou:** reported that protective effect of Baicalin on carbon tetrachloride induced liver injury by activating PPAR $\gamma$  and inhibiting TGF $\beta$ 1. The study was carried out for 8 weeks and herbal drug was Baicalin. The pathological and biochemical findings were investigated such as Decreased Hy, steatosis, liver necrosis, and fibrotic septa formation. Reduced TGF- $\beta$  and PPAR $\gamma$ <sup>[104]</sup>.
- 8) **Y. Feng, N. Wang, X. Ye et al.:** reported that Hepatoprotective effect and its possible mechanism of *coptidis rhizome* aqueous extract on CCl<sub>4</sub> induced chronic liver hepatotoxicity in rats. The study was carried out for 8 weeks and herbal drug was *Coptidis rhizome* aqueous extract. The pathological and biochemical findings were investigated such as reduced Tbil and AST. Improved histological changes. Reduced SOD and Erk1/2 inhibition<sup>[105]</sup>.
- 9) **G.-Y. LI, H.-Y. Gao, J. Huang, J. LU, J.-K. Gu, and J. –H. Wang.:** reported that hepatoprotective effect of Cichorium intybus L., a traditional Uighur medicine, against CCl<sub>4</sub> induced hepatic fibrosis in rats. The study was carried out for 8 weeks and herbal drug was *cichorium intybud* L. extract. The pathological and biochemical findings were investigated such as reduced ALT, AST, Hyp, and histopathological changes. Increased GSH, SOD; reduced MDA. Reduced TGF- $\beta$ 1 and  $\alpha$ -SMA<sup>[106]</sup>.
- 10) **C. Luo, Z. –X. Chen, X.-H. Tan et al.:** reported that Therapeutic effect of fuzhenghuayu decoction in a CCl<sub>4</sub>-induced liver cirrhosis rat model and on

hepatic stellate cell activation. . The study was carried out for 8 weeks and herbal drug was fuzhenghuayu decoction. The pathological and biochemical findings were investigated such as Reduced ALT, AST, and hepatocyte apoptosis. Decreased collagen deposition and inflammatory cell infiltration and reduced  $\alpha$ -SMA and Hyp<sup>[99]</sup>.

- 11) **X.-P. Tian, Y.-Y. Yin, and X. Li,:** reported that Effects and mechanisms of acremoniumterricola milleretal mycelium on liver fibrosis in cirrhosis rats. The study was carried out for 8 weeks and herbal drug was Acremoniumterricola milleretal mycelium. The pathological and biochemical findings were investigated such as Decreased HA, laminin and procollagen type III levels, Hyp. Improved pathological changes. Restored SOD and GSH-Px, inhibited lipid peroxidation. Decreased TGF- $\beta$ , Smad2/3 phoshorylation and increased Smad7 inhibitor<sup>[107]</sup>.
- 12) **Z. -C. Wang, S. Yang, J.-J. Huang, S.-L. Chen, Q.-Q. Li, and Y. Li,:** reported that Effect of Rougan Huaqian granules combined with mesenchymal stem cell transplantation on liver fibrosis in cirrhosis rats. The study was carried out for 8 weeks and herbal drug was Rougan Huaqian granules. The pathological and biochemical findings were investigated such decreased AST and HA, reduced  $\alpha$ -SMA, LN, Col I, Col III, Col IV, and MMP-2<sup>[108]</sup>.
- 13) **F.-R. Yang, B.-W. Fang, and J.-S. Lou:** reported that Effects of Fufang Biejia Ruangan Pills on hepatic fibrosis in vivo and in vitro. The study was carried out for 8 weeks and herbal drug was Fufang Biejia Ruangan Pills. The pathological and biochemical findings were investigated such decreased ALT, AST. Reduced collagen deposition and improved hepatic lesion . reduced hyaluronic acid Col IV, type III procollagen laminin, TGF- $\beta$ 1, and Smad3<sup>[109]</sup>.
- 14) **C. Zhang, Y. Wang H. Chen et al.:** reported that protective effect of the herbal medicines Ganfukang against carbon tetrachloride induced liver fibrosis in rats. The study was carried out for 8 weeks and herbal drug was Ganfukang. The pathological and biochemical findings were investigated such as decreased ALT and AST. Ameriolated ductular proliferatio. Reduced  $\alpha$ -SMA, MMP-2 and TIMP-1, synthesis of collagen, and activation of the Wnt/beta-catenin<sup>[110]</sup>.

- 15) **W. Li, Y. Wu, C. Zhu, Z. Wang, R. Gao and Q. Wu:** reported that anti-fibrosis effect of Huisheng oral solution in CCl<sub>4</sub>- induced hepatic fibrosis in rats. The study was carried out for 8 weeks and herbal drug was Huisheng oral solution. The pathological and biochemical findings were investigated such as The study was carried out for 8 weeks and herbal drug was Ganfukang. The pathological and biochemical findings were investigated such as inhibition of collagen formation and improved liver function. Reduced Smad3, TGF- $\beta$ 1,  $\alpha$ -SMA, and TIMP-1<sup>[111]</sup>.
- 16) **A. N. B. Singab, N. A. Ayoub, E. N. Ali, and N. M. Mostafa:** reported that antioxidant and hepatoprotective activities of Egyptian morceous plants against carbon tetrachloride-induced oxidative stress and liver damage in rats. The study was carried (Moraceae) leaves and fruits and *Morus alba* Linn. Root bark. The pathological and biochemical findings were investigated such as reduced ALT, AST and ALP, and total bilirubin. Improved hepatocellular architecture. Restored antioxidant related content<sup>[112]</sup>.
- 17) **H. B. Cai, X. G. Sun Z. F. Liu et al:** reported that effects of dahuangzhechong pills on cytokines and mitogen activated protein activation in rats with hepatic fibrosis. The study was carried out for 9 weeks and herbal drug was dahuangzhechong pills. The pathological and biochemical findings were investigated such as decreased ALT, AST, HA, Laminin, type IV collagen, and procollagen III and reverses hepatic fibrosis. Reduced  $\alpha$ -SMA, serum TNF ASIL-13, p38MAPK, and Erk phoshorylation<sup>[113]</sup>.
- 18) **J. –X. Du, P. Liu et al.:** reported that the chinese herbal medicines Xiayuxue Decoction inhibits the liver angiogenesis in rats with carbon tetrachloride-induced liver fibrogenesis. The study was carried out for 9 weeks and herbal drug was Xiayuxue decoction. The pathological and biochemical findings were investigated such as inhibits liver injury, fatty degeneration, and collagen deposition. Blocked CD31, VWF, VEGF, VEGFR2, DAF,  $\alpha$ -SMA, and MMP-2 and MMP-9 activities<sup>[114]</sup>.
- 19) **D. –Z. Shen, Q. Tao, J. –X. Du et al:** reported that Effetcs of Yiguanjian Decoction on liver cirrhosis formation a differential proteomics study in rats.

The study was carried out for 9 weeks and herbal drug was Yiguanjian decoction. The pathological and biochemical findings were investigated such as Increased Cu/Zn SOD, DJ-1, glutathione S-transferase Yb-1 subunit, and aldo-keto reductase family 7, A2<sup>[115]</sup>.

**20) J. –C. Shu, L. –X. Chen and Y. –F. Lu:** reported that the Preliminary study on mechanism of therapeutic effect of Huguangjiexian decoction on hepatic fibrosis was done. The study was carried out for 9 weeks and herbal drug was Huagnjiexian decoction. The pathological and biochemical findings were investigated such as inhibition of collagen type I, collagen type III, TGF- $\beta$ 1, and PDGF-BB<sup>[116]</sup>.

**21) Y. –P. Mu, X. –R. Chen, and T. –F. Lu:** reported that the effect of Xiaozheng Rongmu powder for the treatment of liver cirrhosis in rats was studied. The study was carried out for 9 weeks and herbal drug was Xiaozheng Rongmu powder. The pathological and biochemical findings were investigated such as changes in ALT, AST and Tbil are milder and with hepatocytes mitosis<sup>[117]</sup>.

### **3.2 Gomutra Ark<sup>[62]</sup>: Various medicinal properties of gomutra ark**

**22) Gosavi D. D. Sachdev D. Salwe K.:** stated that Introduction In Sushrita Samhita Gomutra (Cow urine) has been described as the most effective substance / secretion of animal origin with innumerable therapeutic values. In India, drinking of cow urine has been practiced for thousands of years. All the five products such as urine, milk, ghee, curd and dung obtained from cow possess medicinal properties, and are used singly or in combination with some other herbs against many diseases including Cancer, AIDS and Diabetes. 1,2 This kind of alternative treatment, termed as "cowpathy". Immunomodulatory agents are used to either suppress or stimulate the immune responses. Although there are claims that cow urine increase antioxidant enzymes still scientific studies are required to support this. 5 Cow urine patented (U.S. Patents No. 6896907 and 6,410,059) for its medicinal properties recently, particularly for its use along with antibiotics for the control of bacterial infection and fight against cancers. 6 Practitioners of

Ayurvedic medicine from India routinely use cow urine as a remedy to treat many common disorders. In most of the cases the efficacy of this treatment regimen is non proved. However, only few attempts have been made to correlate scientifically the nature of cow urine. There are some studies on the use of cow urine but the studies on Gomutra ark which is prepared by distillation of the cow urine and more relatable due to its lower ammonia content, are scarce. In order to correlate, ancient and traditional knowledge of use of cow urine with the modern day, scientific methodologies and parameters, we decided to conduct this study, regarding use of Gomutra Ark as Immunomodulatory and antioxidant agent<sup>[77]</sup>.

**23) Randhava Gurpreet K. Sharma R,:** reported that the grim scenario where presently about 70% of pathogenic bacteria are resistant to at least one of the drugs for the treatment, cue is to be taken from traditional/indigenous medicine to tackle it urgently. The Indian traditional knowledge emanates from ayurveda, where *Bos indicus* is placed at a high pedestal for numerous uses of its various products. Urine is one of the products of a cow with many benefits and without toxicity. Various studies have found good antimicrobial activity of cow's urine (CU) comparable with standard drugs such as ofloxacin, cefpodoxime, and gentamycin, against a vast number of pathogenic bacteria, more so against Gram-positive than negative bacteria. Interestingly antimicrobial activity has also been found against some resistant strains such as multidrug-resistant (MDR) *Escherichia coli* and *Klebsiella pneumoniae*. Antimicrobial action is enhanced still further by it being an immune-enhancer and bioenhancer of some antibiotic drugs. Antifungal activity was comparable to amphotericin B. CU also has anthelmintic and antineoplastic action. CU has, in addition, antioxidant properties, and it can prevent the damage to DNA caused by the environmental stress. In the management of infectious diseases<sup>[78]</sup>.

**24) Rajapandhiyan K., Shanthi S, Murugan AM, Muthu GA, Singh AJ:** They suggested that *Azadirachta indica* have been used in traditional systems of medicine for a various of diseases. In the present study, Cow urine extract of *Azadirachta indica* was evaluated for its antimicrobial activity against MDR Clinical isolates. Antimicrobial activity was evaluated towards five MDR

pathogenic strains of bacteria. The results indicated that Cow urine extract of *A.indica* more antibacterial activity in comparison of its organic fraction for MDR *E.coli* and, *Klebseilla pneumonia* . The phytochemical test suggests that constituents for all the 20 days were positive for flavonoids, alkaloids, quinine, coumarin, tannin, saponin and phenol. Antimicrobial activities were correlated with chemical compositions of both organic extracts and Cow urine extract of *A. indica*<sup>[79]</sup>.

**25) Kumar S. :** He reported that it is a comparative study was conducted on the levels of effectiveness, of natural remedies such as cow's urine, lemon, boiled rice water, Neem extract etc. in curing dandruff and inhibiting the growth of the causative fungus *Malassezia*. Various plating techniques were applied using modified Oil - Potato Dextrose Agar as the nutrient medium for the fungal growth. Cow's urine was found to be more stable and effective in inhibiting the fungus, along with boiled rice-water<sup>[80]</sup>.

**26) Kekuda PT, Nishanth BC, Kumar PS, Kamal D, Sandeep M, Meghraj HK,:**

They suggested that Cow, often called *Kamadhenu*, has been considered as a sacred animal in India. The present study was undertaken to determine antibacterial, antifungal and anthelmintic activity of Cow urine concentrate (CUC) which is obtained by complete evaporation of cow urine. The antibacterial activity was tested against Gram positive and Gram negative bacteria by disc diffusion method. Antifungal activity was tested against species of *Aspergillus* by Agar well diffusion method. Anthelmintic activity was studied using adult Indian earthworm model. Marked inhibition of Gram positive bacteria was observed by the CUC. Inhibition of fungi was found to be dose dependent. Among fungi tested, *A. niger* was more affected than others. In anthelmintic assay, concentration dependent mortality of worms was observed and the effect by CUC was found to be more superior as compared to the standard drug Piperazine citrate. The antimicrobial and anthelmintic activity of CUC may be due to the presence of constituents present in it. The CUC could be used in the treatment of diseases caused by pathogenic bacteria, opportunistic

fungi and parasitic helminthes. Further studies on isolation of inhibitory components and in vivo experiments are to be carried out<sup>[81]</sup>.

**27) Khanuja SP, Kumar S, Shasany Ak, Arya JS, Darokar MP.:** They reported that the invention relates to a novel pharmaceutical composition contains an effective amount of bio-active fraction from cow urine distillate as a bioavailability facilitator and pharmaceutically acceptable additives selected from anticancer compounds, antibiotics, drugs, therapeutic and nutraceutic agents, ions and similar molecules which are targeted to the living beings<sup>[87]</sup>.

**28) Raja W, Agrawal RC.:** HE reported that Cow, *Bos indicus* is a most valuable animal in all veda and it is called as the mother of all. In present investigation, the anticarcinogenic activity of cow's urine were evaluated using two stage in swiss albino Mice, induced by a single application of 7, 12-dimethylbenz(a)anthracene ( 104 µg/ 100µl acetone) and one week latter, promoted by repeatedly application of croton oil (1% in acetone/ thrice a week ) till the end of the experiment (16 wweeks). The tumor incidence, Tumor yield, tumor burden and cumulative number of papillomas wee found to be higher in control ( without cow urine treatment) as comapared to experimental animals ( Cow urine treated). The difference in the value of the resut of experimental groups were statistically analysed and found to be significant in comparision to control group ( $p < 0.05$ ). In conclusion, the present study demonstrates the chemopreventive potential of cow urie on DMBA induced skin tumorigensis in swiss albino rats<sup>[89]</sup>.

**29) Jain NK, Gupta VB, Garg R, Silawat N.:** The object of this survey was to evaluate efficacy of cow urine therapy on various cancer patients who were reported across from different state of India. Total 68 cancer patients reported during the survey from 8 April 2007 to 15 April 2007. During survey, out of 68 patients, 7.35% patients withdraw themselves from the treatment and 63 (92.64%) patients continued the therapy. There was a high proportion (30.87%) of throat cancer and the other prevalent cancer was breast cancer (14.70%) followed by cervix and uterine cancer (5.88%),. The symptoms (pain, inflammation, burning sensation, difficulty in swallowing, irritation, etc.) of

cancer patients were categorized into severe, moderate and mild categories, respectively. Intensive study of the data of cancer patients revealed that the degree of severe, moderate and mild symptoms were 82.16%, 15.8% and 1.58% on the first day and 7.9%, 55.3% and 36.34% on the eighth day, respectively and The activity was found to be increased<sup>[90]</sup>.

**30) Chauhan RS, Singhal L:** The immunomodulatory effect of Kamdhenu ark was studied on 20 mice divided into 2 groups. Groups I was kept as control while group II mice were given 1 ml Kamdhenu ark in water for a period of 90 days. Results indicated that there was increased B- and T- lymphocyte blastogenesis, increased IgG, IgA antibody titres in mice treated with Kamdhenu ark in comparison to controls<sup>[91]</sup>.

**31) Hiren N. Hirapara, Vishal M. Ghorl, Ashish . Anovadiya, Chandrabhanu R. Tripathi,:** They suggested to evaluate wound healing activity of cow urine ark in diabetic rats. Streptozotocin-induced diabetic Wistar albino rats were randomly divided into six groups ( $n = 6$ ). Three groups - diabetic control, active control (glibenclamide), and treatment (cow urine ark) were operated for excision wounds (EWs) EWs showed significantly increased wound closure in the treatment group as compared to the diabetic as well as active control groups Wound contraction was also significantly improved. The cow urine ark could be potentially effective in promoting healing of diabetic wounds by increasing granulation tissue formation and collagen content<sup>[92]</sup>.



**4] AIM AND OBJECTIVE:**

**4.1 AIM :** Hepatoprotective Activity of Gomutra Ark in Carbon Tetrachloride induced Liver Cirrhosis in wistar rats.

**4.2 OBJECTIVE:**

- 1) To assess the biochemical parameters of Gomutra Ark in Carbon tetrachloride induced Cirrhosis in wistar rats.
- 2) To evaluate the Hepatoprotective effect of Gomutra Ark in Liver Cirrhosis induced by Carbon tetrachloride in wistar Rats

**5] PLAN OF WORK:**

**5.1 Review of literature:** To carry out review of literature to know the fact related to Liver Cirrhosis, animal model required to study liver Cirrhosis, and to know about various plants and preparations possessing such activity.

**5.2 Collection, identification and authentication of product:** It was done by Govigyan Anusandhan Kendra, Deolapar, Nagpur.

**5.3 Permission from IAEC for carrying out animal experimentation:** To take prior permission from Institutional Animal ethics Committee (IAEC), Datta meghe Institute of medical sciences [deemed to be University] (DMMS(DU)/IAEC/2018-19-08) constituted under the norms given by committee for the Poupouse of control and Supervision on Experiments on Animals (CPCSEA).

**5.4 Pharmacological Screening: Animals:** Healthy rats of male sex weighing about 150-200gms.

**5.5 Grouping of animals:** Animals will be divided into 5 groups containing 5 animals in each group.

**5.6 Data analysis:** Biochemical and histopathological finding were done.

**5.7 Result**

**5.8 Disscusion**

**5.9 Conclusion**

## 6] MATERIAL AND METHODS:

### 6.1 MATERIALS

#### 6.1.1 Collection and Authentication of drug Material :

Gomutra ark was collected from Govigyan Anusandhan Kendra, Deolapar, Nagpur of Maharashtra on January 2019. The product was authenticated by Govigyan Anusandhan Kendra, Deolapar, Nagpur .

#### 6.1.2 Chemicals and reagents :

**A. Standard drug :-** Silymarin suspension (silybol, Microlabs). This is an allopathic formulation of Acute liver toxicity.

It is mainly used in the treatment of liver disorder.

**B. Others Chemicals and Reagents:-**

Olive oil (Vehicle for CCl<sub>4</sub>)

Inducing agent<sup>[40]</sup>: Carbon tetrachloride : Carbon tetrachloride (CCl<sub>4</sub>) is a hepatotoxin that causes acute liver injury and, when given repetitively at a low dose, induces liver fibrosis. It is one of the most widely studied inducers of liver fibrosis. Most commonly, a dose of 0.5–2 mL/kg body weight administered twice per week will suffice to induce fibrosis within a few weeks. In the liver, CCl<sub>3</sub> radicals are formed, which induce hepatocyte damage and activation of hepatic stellate cells, leading to the production of extracellular matrix. CCl<sub>4</sub>-induced experimental fibrosis resembles human liver fibrosis caused by alcohol consumption, it serves as an attractive model for chronic toxic liver injury and its consequences on the molecular level.

diethyl ether, formalin (10%) was obtained from sigma chemicals.

The chemicals used and other solutions were all of analytical grade. All drugs and chemicals were prepared immediately before used.

**6.1.3 Instruments and equipment:** Centrifuge, weighing balance, pipettes, test tube/racks, timer, biochemical analyser, microscope.

#### 6.1.4 Experimental animals;

**Animal strains house of** –Male wistar rats wer obtained from animals house of Datta Meghe Medical college, Sawangi, Wardha.

**Age-** 4-5 months

**Body weight-** 180-250gm

**IAEC APPROVAL:** All animals experiments were conducted with prior permission of Institutional ethical committee (IAEC).

**Housing condition:** All the experimental and housing conditions of animals were maintained as per CPCSEA guidelines. Animals were kept in group of five in propylene plastic cages with sterilized husk as bedding material. Animals were provided standard feeding pellets (golden feeds, New Delhi) and water *ad libitum* temperature was maintained at  $22\pm 2^{\circ}\text{V}$ , with light and dark cycle of 12;12 hrs. The animals were transferred to the laboratory at least 1 hr before experiment for proper acclimatization. Animals ere acclimatized to the experimental conditions for a period of one week before actual experimentation. The care and handling of animal were in accordance with laboratory with the internationally accepted standard guidelines for animal (CPCSEA) permission and approval for animal studies obtained from the Institutional Animal Ethics committee (IAEC) of Datta Meghe Medical College, Sawangi, Wardha.

#### 6.2 DETERMINATION OF HEPATOPROTECTIVE ACTIVITY:

Male Wistar rats weighing 180-250gms were used for study. Male wistar rats (180 250gm) were seperatly group housed in ambient room temperature ( $27\pm 2^{\circ}\text{C}$ ) and 4234235relative humidity ( $50\pm 5\%$ ), maintained at  $12\pm 1$  hr dark-light cycle. Food and water were available *ad libitum*. Animals were acclimatized to the experimental condition for a perod of one week before actual experimentation. The care and handling of animal were done in accordance with laboratory with the standard guidelines for animals (CPCSEA) permission and approval for animal studies obtained from Institutional Animal Ethics Committee (IAEC) of Datta Meghe Medical college, Sawangi, Wardha .

**6.2.1 EXPERIMENTAL DESIGN**

Rats were divided into five groups with six animals each. The first group receive oral dose of the vehicle (1ml/kg), the second group receives Carbon Tetrachloride 1ml/kg i.p. Third group received silymarin (100mg/kg), fourth and fifth group receives oral dose of 0.9ml/kg and 1.8ml/kg respectively

**A) Treatment protocol :**

. The rats were randomly divided into 5 groups of 6 rats each.

**Table no. 4: treatment protocol for all groups:**

Sr no .	Test group	No. of animals	Drugs
1.	Normal control group	6	Olive oil for 10 days
2.	Inducing group	6	Olive oil 1ml/kg and CCl <sub>4</sub> i. p. every 72 hrs for 3 days
3.	Standard group	6	Mixture of CCl <sub>4</sub> ml/kg and olive oil 1ml/kg every 72 hrs 3 doses + silymarin (100mg/kg) for 10 days.
4.	Test group I	6	CCl <sub>4</sub> (1ml/kg) and olive oil 1ml/kg i.p. (1:1) every 72 hrs 3 doses + Gomutra Ark (0.9 ml/kg) for 10 days.
5.	Test group II	6	CCl <sub>4</sub> 1ml/kg and olive oil 1ml/ kg i.p. (1:1) every 72 hrs 3 doses + Gomutra ark (1.8 ml/kg) for 10 days

**B) Experimental procedure:**

- 1) Animals were obtained and acclimatized for one week
- 2) Inducing agent CCl<sub>4</sub> was given with olive oil as solvent (1:1) every 72 hrs 3 doses to Inducing group, standard group, Test group I and Test group II, Normal control group was give olive oil for 10 days.
- 3) After inducing CCl<sub>4</sub> in animals, to check biochemical parameters blood sample of 2ml from each animal was collected with retro-orbital route, enzyme markers such as ALT,AST and ALP were estimated and changes were observed for all groups.
- 4) Standard group animals were given silymarin (100mg/kg) for 10 days, test group I was given GoA (0.9 ml/kg) for 10 days and Test group II was given GoA (1.8 ml/kg) for 10 days .
- 5) Biochemical parameters such as ALT,AST and ALP were observed and noted down.
- 6) Next day, animal were sacrificed using diluted Diethylether (2ml/kg) and there liver was obtained for histopathological study. They were fixed in 10% neutral buffered formalin as described by luna.

**Acute Toxicity Study On Gomutra Ark was Performed and upto 32ml/Kg was found to be Safe<sup>[122]</sup>.**

**6.2.2 DOSE CALCULATION:****Pagets and barns formula:**

200gm rat dose =  $0.018 \times$  adult dose

1kg rat dose =  $0.018 \times$  Adult dose  $\times 5$

**Therapeutic Dose of GoA in human = 10ml/kg**

so, 1kg Dose of rat =  $0.018 \times 10 \times 5 = 0.9\text{ml}$

twice of this dose was also taken i.e. 1.8ml

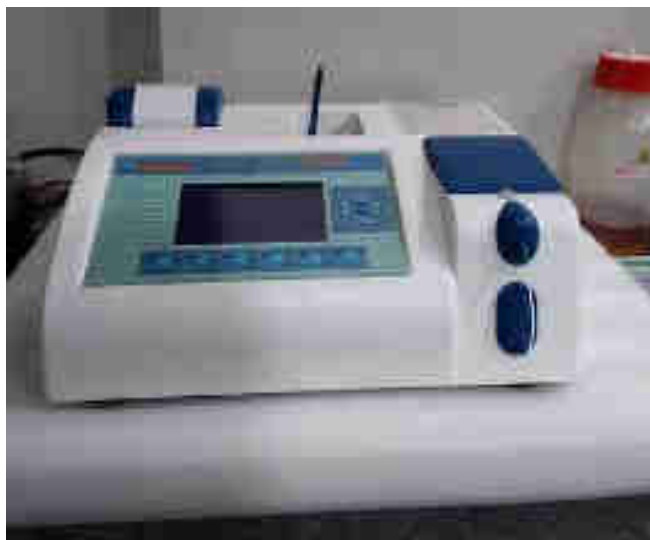### 6.3 EVALUATION OF HEPATOPROTECTIVE ACTIVITY:

#### 6.3.1 Estimation of biochemical parameters<sup>[118,119-121]</sup>.

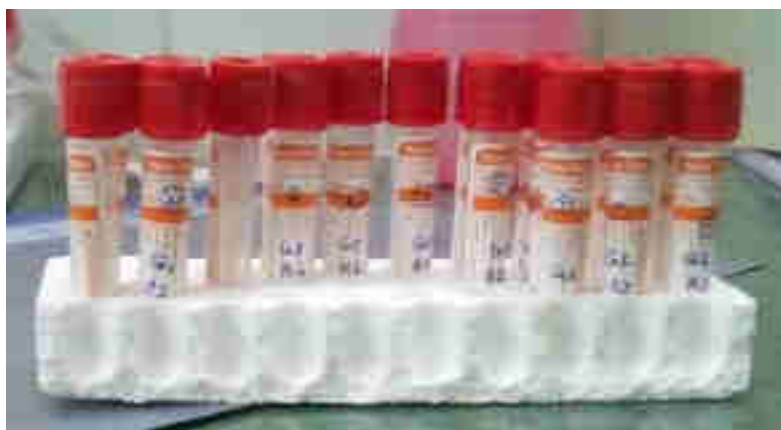At the end of experimental period , Blood were collected by Retro-orbital plexus and serum was separated with the help of centrifugation at 2000 rpm for 10 mins for biochemical analysis. Liver Marker enzymes such as Aspartate amino transaminase (AST) Alanine amino transaminase (ALT) and alkaline phosphatase (ALP) kits were estimated were obtained from local chemical shop.



**Fig no. 12.: Centrifugation apparatus**



**Fig no. 13: Autoanalyser for biochemical analysis.**



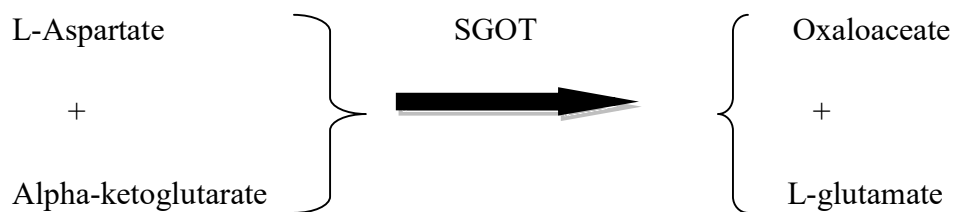
**Fig no.14: Test tube according to groups for biochemical analysis.**

**a) SGOT<sup>[123]</sup>:**

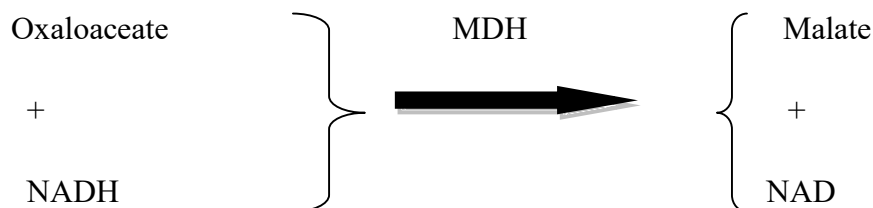This reagent kit for constitutive estimation of glutamate oxaloacetate transaminase activity in serum or plasma it is present in all human tissue of the body. It is also present in large amount in liver,kidney,heart and skeletal muscle. when any of these organs are damaged or diseased,serum GOT level rises.The rise is proportional to the extent of damage or disease.

**Principle:**In this reaction L-Aspartate and Alpha-ketoglutarate react in the presence of GOT in the sample to yield oxaloacetate and L-glucomate.





The reaction is monitored by measurement of decrease in absorbance of NADH at 340nm.



The rate of absorbance is proportional to GOT activity in sample.

#### Reagent Composition:

**Table no.5: reagent(1 and 2) composition at pH 8.0 ± 0.1 at 25°C (SGPT):**

Active Ingredients (reagent 1)	Concentration
NADH	0.1 mmol
LDH	>1000U/L
MDH	>1000U/L
Reagent 2	
Buffer	50 mmol/L
L-aspartic acid	150mmol/L
A-KG	10 mmol/L

also contain non-reactive fillers and stabilizers.

#### Preparation Of Working Reagent :

FOR 20 x 1.1 ml.

Add 1.1 ml of 2 SGOT to one table of 1 SGOT .Mix well to dissolve and wait for 15 minutes prior to use. The working reagent is stable for 30 days at 2-8°C.

FOR 5x10 ml.

Carefully transfer the content of 1 SGOT (powder) into the bottle containing 20 ml of 2 SGOT (buffer). Mix gently to dissolve completely. Wait for 5 minutes before use. The working reagent is stable for 4 months at 2-8°C.

FOR 5x20 ml.

Carefully transfer the content of 1 SGOT (powder) into the bottle containing 50 ml of 2 SGOT (buffer). Mix gently to dissolve completely. Wait for 5 minutes before use. The working reagent is stable for 4 months at 2-8°C.

FOR 4x50 ml.

Carefully transfer the content of 1 SGOT (powder) into the bottle containing 50 ml of 2 SGOT (buffer). Mix gently to dissolve completely. Wait for 5 minutes before use. The working reagent is stable for 4 months at 2-8°C.

#### **Specimen Collection:**

Fresh clear serum under fasting condition with no hemolysis is the specimen of choice. Plasma collected with anticoagulants such as heparin or EDTA may be used.

The samples were prepared, no readings taken were according to sample collection. Sample volume was 100  $\mu$ l at the interval of 30 sec and factor was 1746, flow cell temperature was 37°C and wavelength was 340 nm. Zero setting was taken with distilled water.

**Table no. 6: working reagent and sample to be taken in ml into pipette.**

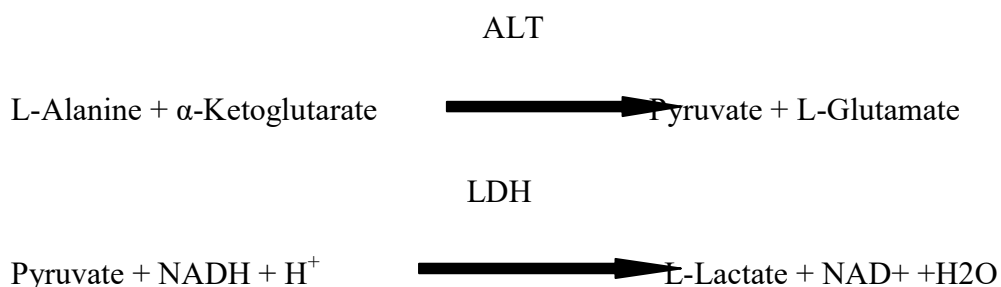
Pipette into test tube	Test
Working reagent(ml)	1.0
Sample (ml)	1.0

Mix and after incubation at 37° C for 60 seconds, measure the absorbance at an interval of 30 seconds for 2 mins at 340 nm

NORMAL VALUE: 3-3.5U/L (37°C)

a) SGPT<sup>[124]</sup>:

Clinical Significance ALT is widely distributed in tissues with the highest concentrations found in the liver and kidneys. Even so, ALT is considered more liver-specific than AST. Elevated levels of ALT are often only observed in liver diseases such as cirrhosis, hepatitis, or metastatic carcinoma. However, there can be elevated levels of ALT with infectious mononucleosis, muscular dystrophy, and dermatomyositis

**Principle:**

ALT catalyzes the transfer of the amino group from L-alanine to  $\alpha$ ketoglutarate resulting in the formation of pyruvate and L-glutamate. Lactate dehydrogenase catalyzes the reduction of pyruvate and the simultaneous oxidation of NADH to NAD. The resulting rate of decrease in absorbance is directly proportional to ALT activity.

**Reagents**

After combining R1 and R2 the reagent contains: L-alanine 500mM,  $\alpha$ ketoglutaric acid 15mM, LDH(microbial) >2000IU/L, NADH >0.18mM, Buffer 100mM, pH 7.5 $\pm$ 0.1, Sodium azide 0.25%, Stabilizers.

**Specimen Collection and Storage** Hemolyzed samples cannot be used as red cells contain ALT. ALT in serum is stable for three days at room temperature (15-30°C), seven days refrigerated (2-8°C), and thirty days frozen (-20°C).

**Test Procedure**

(Automated) Wavelength:	340 nm
Assay Type:	Kinetic
Sample/Reagent Ratio:	1:10
Reaction Direction:	Decreasing
Temperature:	37°C
Lag Time:	60 seconds
Read Time:	60 seconds
Low Normal:	5 U/L
High Normal:	34 U/L

Application Parameters for various automated instruments are available. Please contact the Technical Service Department for specific information.

**Expected Value:**

4 to 24 IU/L (30°C)

4 to 36 IU/L (37°C)

Since the expected values are affected by age, sex, diet, and geographical location, each laboratory is strongly urged to establish its own reference range for this procedure..

**c) ALP<sup>[125]</sup>:**

ALP test kit is for the quantitative determination of ALP concentration in human serum or plasma. Alkaline Phosphatase (ALP) belongs to the Hydrolase class of enzymes and catalyses the splitting of organic phosphate esters, with optimum activity at pH 10.20 is ubiquitously distributed throughout the body. However, liver, bone and placenta contain very high concentrations of ALP. Hence, increase in ALP activity is usually related to hepatobiliary and bone disorders. Elevated ALP levels are seen in toxic hepatitis, infective hepatitis, intra and extra hepatic obstructions.

**Principle****Reagent Composition:****Table no.7: Reagent composition (ALP):**

2-Amino-2-methyl-1-propanol buffer pH 10.4	0.70 mmol/L
p-Nitrophenylphosphate	12.00 mmol/L
HEDTA	1.55 mmol/L
Mg Acetate	1.50 mmol/L

Preservatives and stabilizers

**Storage And Stability**

The components of the kit, stored at 2 - 8 °C, will remain stable until the expiry date stated

on the label

**Sample / Specimen And Storage**

Serum or heparinized plasma.

Use samples free from hemolysis. Serum kept in the refrigerator at 2-8 °C will remain stable

for 7 days

**Test Procedure**

Primary wavelength..... 405 nm

Temperature..... 37 °C

Prewarm the Reagent to reaction temperature.

**Table no. 8: blank , sample and reagent in ml:**

	Blank (ml)	Sample (ml)
Distilled water	1.000	--
ALP Reagent	--	1.000
Sample	--	0.025

Mix & take the first reading after 30 Sec. and take THREE additional readings at 60 Sec. intervals. Calculate mean absorbance change per minute ( $\Delta A/\text{min.}$ )

### Normal Values

Adults Women: 42 – 141 U/L

Men: 53 – 128 U/L

It is strongly recommended that each laboratory establish its own normal range

### System Parameters

Mode Kinetic

Factor: 2757

Wave length : 405 nm

Units : U/L

Flow cell Temp.: 37 °C

Blank : Distilled water

Reagent volume : 1000  $\mu\text{L}$

Sample volume : 25  $\mu\text{L}$

Lag time : 30 Sec.

Read time : 180 Sec.

Low Normal : 42.00

High Normal : 141.00

### 6.3.2 Estimation of Histopathological studies<sup>[118]</sup>:

Anatomy of liver was studied Immediately after sacrificing the animals. A small portion was fixed in 10% neutral buffered formalin as described by luna. This section of 4-5  $\mu\text{m}$  were taken, stained with haematoxylin and Eosin and histology was studied. The results were expressed in mean  $\pm$  SEM, Student t test, was used for statistical significance between groups.

Rats in all group were killed and livers were dissected out and fixed and processed to paraffin blocks and alcohol dehydration and Xylene clearance. Liver tissue was sectioned

at 5  $\mu\text{m}$  thick and stained with hematoxylin and eosin for routine observation. The section were stained and then sent for grossing

**Things that were observed:** Capsule, lobular Architecture, sinusoidal congestion, hepatocytic activity, portal traid.

#### 6.4 STATISTICAL ANALYSIS

The data were expressed as mean  $\pm$  SEM . Results were analysed statistically by One way ANOVA followed by DUNNET's test using Graphpad instat version 3 and Graphpad prism. The difference was considered significant if  $p < 0.05$ ,  $p < 0.01$ ,  $p < 0.001$ .

## 7) RESULTS

### 7.1 BIOCHEMICAL ANALYSIS:

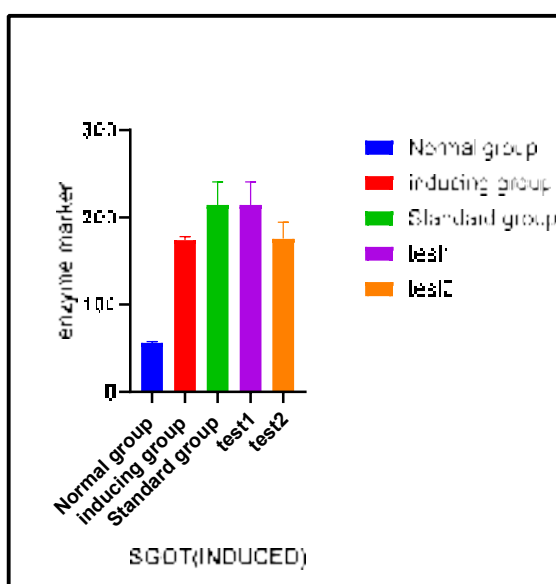
#### 7.1.1.Pre Treatment:

There was statistical increase ( $p < 0.05$ ) in inducing, standard, test group1 and test group2 when compared with normal group.

**Table no.9:Effect of Carbon tetrachloride on liver enzyme marker:**

Parameter	Normal Group	Inducing group	Std group	Test group I	Test group II
SGOT(units/ml)	31.03206±6.22	85.713233±10.79	76.63266±7.451	76.54014±5.056*	71.8707±7.521*
SGPT(units/ml)	56.25875±8.12	173.750333±7.69	214.2032±2.61	214.20257±9.69*	175.516±10.1*
ALP(units/ml)	106.6018±5.02	273.056333±11.0	367.005±2.23	247.88475±1.90*	389.8302±2.0*

**Keys:** Value are mean± SEM for 6 animals in each observation. P denotes statistical significance ( $p < 0.05$ ) the experimental animals were compares to normal group



**Fig no. 15: SGOT level when inducing agent CCl<sub>4</sub> was given to every group.**



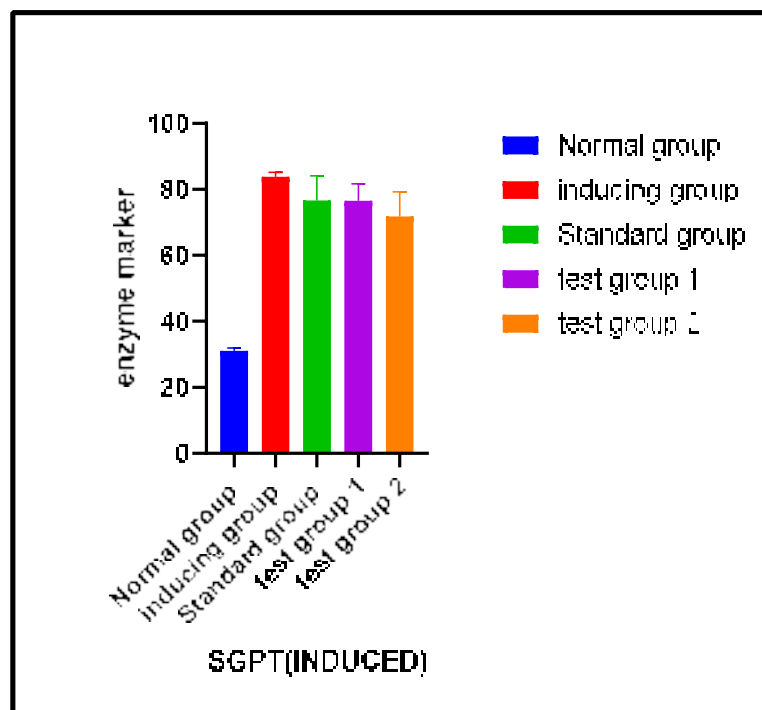


Fig no.16 : SGPT level when inducing agent  $\text{CCl}_4$  was given to every group.

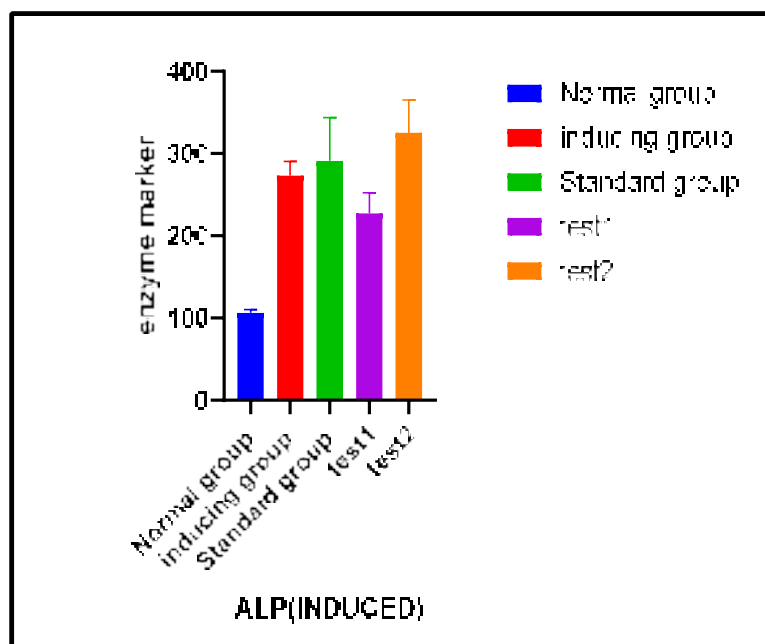


Fig no. 17: ALP level when inducing agent  $\text{CCl}_4$  was given to every group.

### 7.1.2 POST TREATMENT:

There was statistical decrease ( $p < 0.001$ ) in standard, test group 1 and test group 2 when compared with inducing group

Table no.10.: Effect of Carbon tetrachloride on liver enzyme marker

Parameter	Normal Group	inducing group	Standard group	Test group I	Test group II
SGPT(units/ml)	35.03206 $\pm$ 3.12	88.713343 $\pm$ 10.86	40.3596 $\pm$ 1.3359	37.248 $\pm$ 0.76139	37.0099 $\pm$ 1.525569
SGOT(units/ml)	52.25875 $\pm$ 1.70	181.7620 $\pm$ 4.5002	143.281 $\pm$ 3.2506	129.331 $\pm$ 4.8576	125.767 $\pm$ 5.91
ALP(units/ml)	110.5238 $\pm$ 6.02	266.2024 $\pm$ 15.174	116.766 $\pm$ 2.664	139.0892 $\pm$ 19.365	115.2038 $\pm$ 7.086

**Keys:** Value are mean $\pm$  SEM for 6 animals in each observation. P denotes statistical significance  $P^* < 0.01$ ;  $P^* < 0.001$  the experimental animals were compares to inducing group.

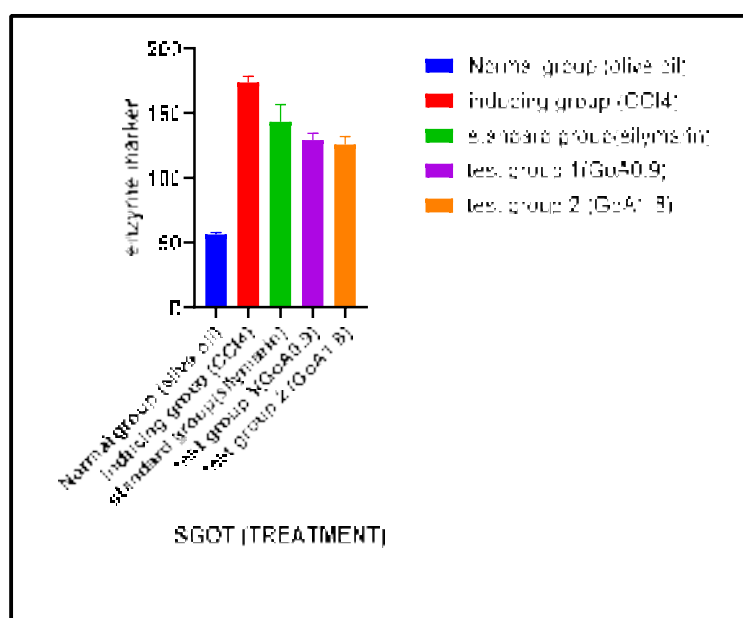


Fig no.18: SGOT level when drug was given to standard , test 1 and test 2 group.

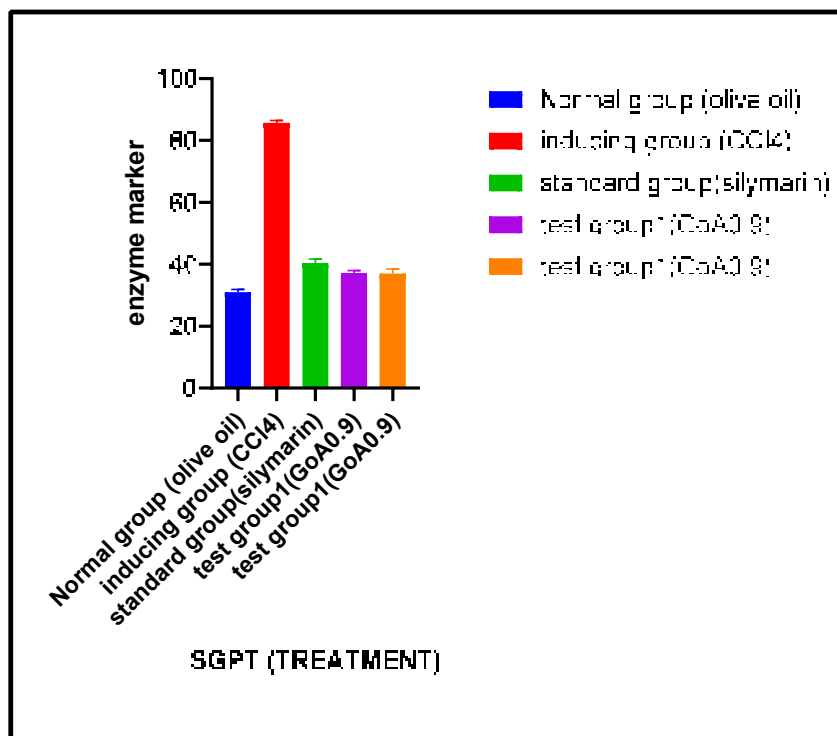


Fig no.19 : SGPT level when drug was given to standard , test 1 and test 2 group

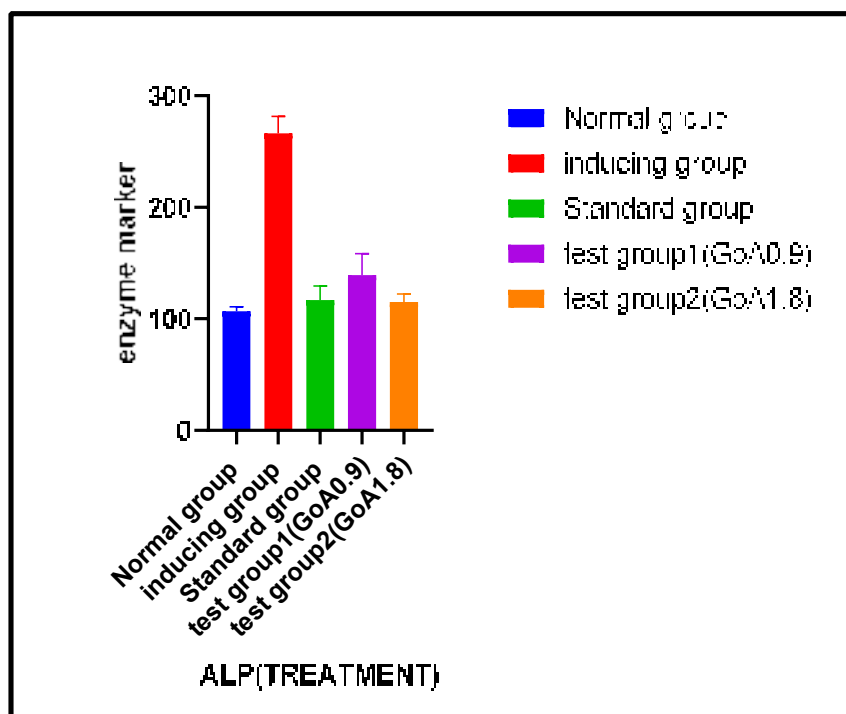
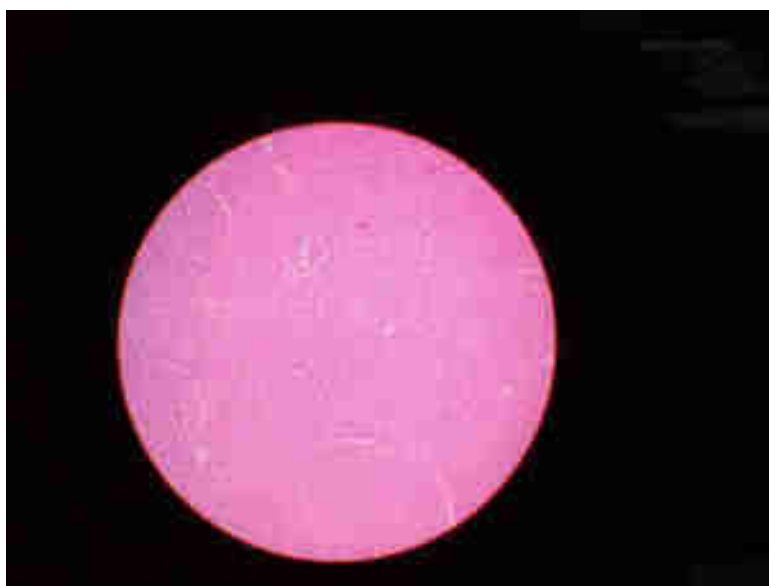


Fig no.20 : ALP level when drug was given to standard , test 1 and test 2 group.

## 7.2 HISTOLOGICAL STUDIES:

### 7.2.1NORMAL GROUP:

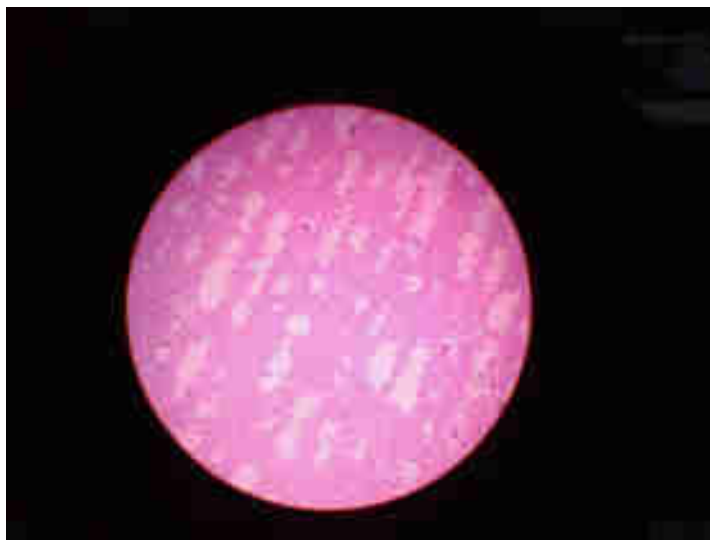1. Capsule appears Normal.
2. Lobular Architecture appear normal.
3. Rare area shows Sinusoidal mild congestion. The regenerative hepatocytic activity is noticed in few focal area.
4. Portal traid appear Normal.



**Fig no21.:histopathology of Normal liver group.**

### 7.2.2INDUCED GROUP:

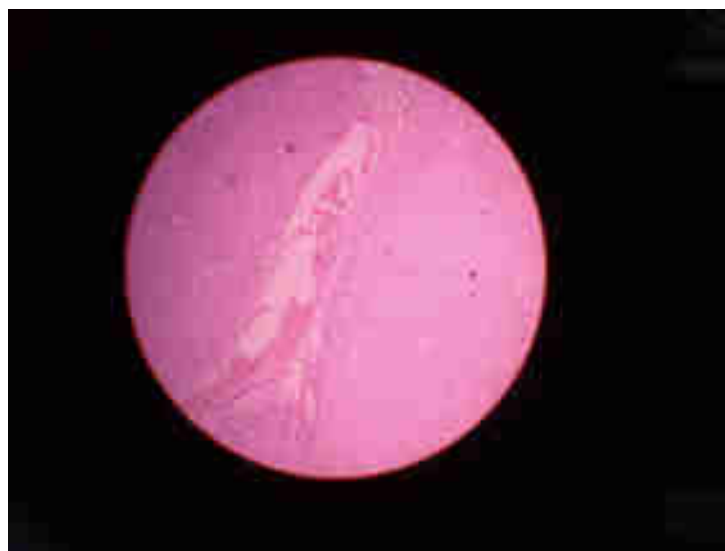1. Capsule appears disturbed.
2. Subcapsular congestion is noticed. Architecture appears dislocated and focal sinusoidal congestion.
3. Hepatocellular necrosis is observed.
4. Portal traid appear disturbed.



**Fig no.22:histopathology of inducing liver group.**

### **7.2.3STANDARD GROUP (SILYMARIN):**

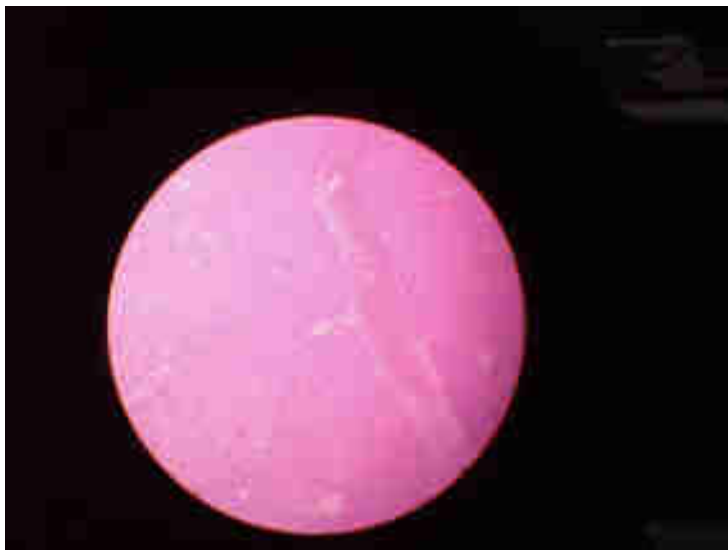1. Capsule appears normal.
2. Hepatic architecture is maintained.
3. Occasional hepatolysis is been accomplished by regenerative activity.
4. Portal traid is unremarkable.



**Fig no.23:histopathology of standard liver group.**

**7.2.4 TEST GROUP 1 (GoA 0.9):**

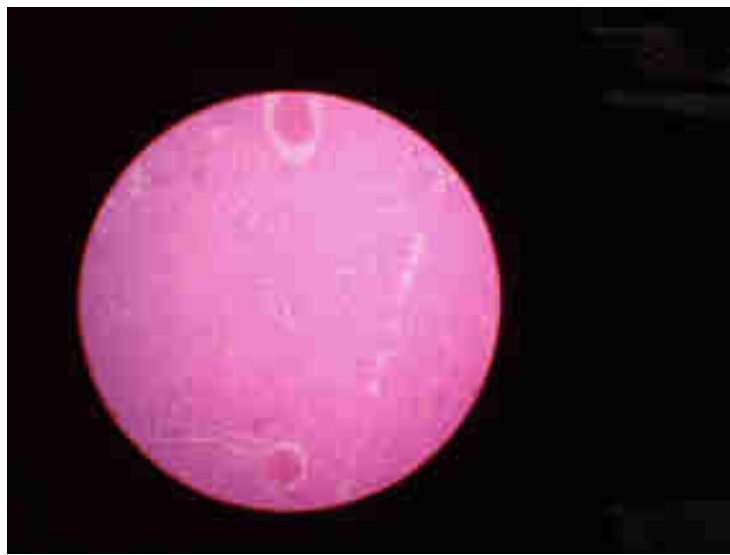1. Capsule appears normal.
2. Sinusoidal show significant congestion so also in central vein Architecture is normal accompanied by regenerative activity.
3. Portal traid appears normal.
4. A few area show **a little fatty changes.**



**Fig no.24:histopathology test group 1 liver group.**

**7.2.5 TEST GROUP 2( GoA 1.8):**

1. Capsule appears normal
2. Sinusoid shows congestion.
3. Architecture appears normal.
4. A few of portal traid show normal acivity.
5. Cental vein appears normal.
6. Heaptocytes at few places shows regenerative activity.



**Fig no.25:histopathology of test group 2 liver group.**

**8] DISCUSSION:**

Liver Cirrhosis basically is a wound healing response to various types of injury, which can progress into liver cirrhosis and even to hepatocellular carcinoma (HCC). The most common causes of liver fibrosis in industrialized countries, are alcohol abuse, viral hepatitis B (HBV) and C (HCV) infections, and metabolic syndromes due to obesity, insulin resistance and diabetes (Blachier et al 2013). In non-industrialized countries, parasitic infections, such as *Schistosoma* species, are also included in liver injury cases.

Cirrhosis has many causes. In the United States, chronic alcoholism and hepatitis C are the most common ones. It is caused due to Alcoholic liver disease, Chronic hepatitis C, Chronic hepatitis B and D, Autoimmune hepatitis, Nonalcoholic steatohepatitis (NASH), Blocked bile duct, drugs, toxins and infections. Many people with cirrhosis have no symptoms in the early stages of the disease. However, as scar tissue replaces healthy cells, liver function starts to fail and a person may experience one or more of the following symptoms like exhaustion, fatigue, loss of appetite, nausea, weakness, weight loss, abdominal pain, spider-like blood vessels (spider angiomas) that develop on the skin. As the disease progresses, complications may develop. In some people, these may be the first signs of the disease. Loss of liver function affects the body in many ways.

The hepatoprotective activity of GoA was evaluated using chemical-induced hepatotoxicity models. Prior studies from our laboratory have reported that carbon tetrachloride produces  $\text{CCl}_3$  radicals, which induces hepatocyte damage and activation of hepatic stellate, leading to production of extracellular matrix. Like in most other models of hepatic fibrosis, TGF- $\beta$ 1 also plays a major role in  $\text{CCl}_4$ -induced liver fibrosis: TGF- $\beta$ 1 is upregulated and maintained throughout the fibrotic process; blocking TGF- $\beta$ 1 expression with siRNA markedly reduces fibrosis. As this robust model allows to study different components of the fibrogenic process in detail, several other factors contributing to  $\text{CCl}_4$ -induced liver fibrosis have been identified: increase in oxidative stress, as seen in animals deficient in fibrogenic growth factor receptor 4 (FGFR4), leads to higher susceptibility to  $\text{CCl}_4$ -induced fibrosis, possibly due to a delayed degradation of  $\text{CCl}_4$ . Decrease of the free radicals, as seen in insulin-like growth factor-1-transgenic mice, ameliorates  $\text{CCl}_4$ -induced fibrosis and leads to decreased levels of secreted TGF- $\beta$ 1 and



reduces the number of activated  $\alpha$ SMA-expressing hepatic stellate cells. Other cofactors include angiotensin II and its receptors and thus damage of hepatic cells which ultimately leads to Liver Cirrhosis in rats. Carbon tetrachloride was taken as it is widely used inducer and causes acute liver injury and it resembles human liver Cirrhosis caused by alcohol consumption etc.

The level for serum Aspartate amino transaminase (AST), Alanine amino transaminase (ALT), and alkaline phosphate (ALP) were taken as an index for hepatotoxicity induced by CCl<sub>4</sub>. The level of marker enzymes of CCl<sub>4</sub> induced were significantly increased when compared to normal and control group.

GoA has been reported to exert several pharmacological properties such as prevention of antibiotic resistance, Fungicide and biofungicide, Antiseptic, Anthelmintic activity, bioenhancer, anticancer properties, Immunostimulant, wound healing activity, Antiulcer activity and so it is said to have hepatoprotective activity but appropriate research work was not done.

The biochemical analysis suggested that hepatotoxicity was induced using Carbon tetrachloride and hepatoprotective activity was observed in silymarin and gomutra ark was given in doses of 0.9 and 1.8ml when compared with toxic group. The level of enzyme marker after administration of drug was decreased.

It was observed in histopathological finding study that hepatoprotective effect of GoA was approximately similar to silymarin which was taken as standard drug. histopathological studies of liver section was done and normal architecture such as central veins, portal tracts, hepatocytes and sinusoids were observed.

Furthermore, The extract was suggested to possess hepatoprotective activity. The activity that GoA possesses were statistically significant.

## 9] CONCLUSION

In present study it was concluded that GoA may significantly have hepatoprotective activity. It has significant effect on biochemical analysis and histopathological studies. The result suggest that GoA has potential hepatoprotective activity and the enzyme marker activity was decreased.

The mechanism of liver injury is through the production of toxic trichloromethyl free radicals ( $\text{CCl}_3$ ) by liver microsomes during the metabolism of  $\text{CCl}_4$ . Free radicals are highly reactive and bind covalently to cell molecules, leading to cell necrosis. Due to the enzymatic activation by  $\text{CCl}_3$  free radicals, elevation of SGOT, SGPT and ALP levels occurs, which was evidenced by the elevation of the above markers ( $P < 0.05$ ) in  $\text{CCl}_4$  treated animals as observed in our study. Treatment with Gomutra ark reduced the elevated enzyme levels in a dose-dependent manner, indicating that it interferes with the action of  $\text{CCl}_3$  free-radicals produced. Since hepatoprotective properties of Gomutra ark were found in this study, the possible mechanism of Gomutra Ark by which the liver function is protected may be attributed to its antioxidant property contributed mainly by volatile fatty acids and free radical scavenging. Further study is needed to evaluate its potential usefulness in clinical conditions associated with liver damage.

**10] REFERENCES:**

- 1) Harold Ellis, CBE FRCB FRCOG, Emeritus Professor of surgery, University of London. Anatomy of liver. Surgery; 29: 12.
- 2) Ozougwu, Jewas C. Ph.d, Physiology and biomedical Research unit, Department of biological science, Rhema University, Nigeria. Physiology of liver. International Journal of research in pharmacy and Bioscience. Volume 4, Issue 8, 2017. ISSN 2394-5893; 13-24.
- 3) Allen SE. The liver: Anatomy, Physiology, Disease and Treatment. 2002 North Eastern University Press, USA.
- 4) Moore KL, Dalley AF. Clinically Oriented Anatomy. 2006 5th Edition Lippincott Williams and Wilkins; 1209.
- 5) Singh I. Textbook of Human Histology with colour Atlas. 2007, 5th Edition Jay Pee Brothers Medical Publishers Ltd; 365
- 6) Butura A. Drug and Alcohol Induced Hepatotoxicity. 2008 Ph. D Thesis Department of Physiology and Pharmacology Karolinska Institutet, Stockholm, Sweden; 55
- 7) Grisham JW. Cell type in rat liver cultures: their identification and isolation. Molecular and Cellular Biochemistry 1983, 53(2); 23 – 33.
- 8) Kmiec Z. Co-operation of liver cells in health and diseases. Advances in Anatomy, Embryology and Cell Biology 2001, 161; 3 – 12.
- 9) Hendriks HF, Brouwer A, Knook DL. Isolation, purification and characterization of liver cell types. Methods in Enzymology 1990, 190; 49 - 58.
- 10) Wanson JC, Bernaert D, May C. Morphology and functional properties of isolated and cultured hepatocytes. Progress in Liver Diseases 1979, 6; 1 - 22.
- 11) Jeejeebhoy K, Phillips MJ. Isolated mammalian hepatocytes in culture. Gastroenterology 1976, 71(6); 1086 - 1096.
- 12) Sirica AE, Pitot AC. Drug metabolism and effects of carcinogens in cultural hepatic cells. Pharmacological Review 1979, 31(3); 205 - 228.
- 13) Smith MT, Wills ED. Effects of dietary lipid and phenobarbitone on the distribution and concentration of cytochrome P-450 in the liver studied by

- quantitative cytochemistry Federation of European Biochemical Society Letters 1981, 127(1); 33 - 36.
- 14) Gebhardt R, Mecke D. Heterogenous distribution of glutamine synthase among rat liver parenchymal cells in situ and in primary culture. EMBO Journal 1983, 2(4); 567 - 570.
  - 15) Breiner KM, Urban S, Schaller H. Endothelial cell-mediated uptake of a hepatitis B virus: a new concept of liver targeting of hepatotropic microorganisms. Hepatology 2001, 34(4); 803 - 808.
  - 16) Knook DL, Blansjaar N, Sleyster EC. Isolation and characterization of kupffer and endothelial cells from the rat liver. Experimental Cell Research 1977, 109(2); 317 - 329.
  - 17) Smedsrod B, Pertoft H, Eggertsen G, Sundstrom C. Functional and morphological characterization of cultures of kupffer cells and liver endothelial cells prepared by means of density separation in per cells, and selective substrate adherence. Cell and Tissue Research 1985, 24 1(3); 639 - 649.
  - 18) Munthe-Kaas AC, Berg T, Seglen PO, Seljelid R. Distribution of lysosomal enzyme in different types of rat liver cells. Experimental cell Research 1976, 99(1); 146 - 54.
  - 19) Knook DL, Seffelaar AM, De-Leeuw AM. Fat-storing cells of the rat liver. Their isolation and purification. Experimental Cell Research 1982, 139(2); 468 - 471.
  - 20) Friedman SL. Hepatic satellite cells: Protein, multifunctional and enigmatic cells of the liver. Physiological Review 2008, 88(1); 125 - 172.
  - 21) Guyton AC, Hall JE. Textbook of Medical Physiology. 2006, 11th Edition, Saunderson Philadelphia, Pennsylvania ; 1116
  - 22) Park BK, Pirmohamed M, Kitteringham NR. The role of cytochrome P450 enzymes in hepatic and extrahepatic human drug toxicity. Pharmacology and Therapeutics 1995, 68(3); 385 – 424.
  - 23) Liu ZX, Govindarajan S, Kaplowitz N. Innate immune system plays a critical role in determining the progression and severity of acetaminophen hepatotoxicity. Gastroenterology 2004, 127; 1760 – 1774.

- 24) Abo T, Watanabe H, Iiai T, Kimura M, Ohtsuka K, Sato K, Ogawa M, Hirahara H, Hashimoto S, Sekikawa H. Extrathymic pathways of T-cell differentiation in the liver and other organs. *International Reviews of Immunology* 1994, 11(1); 61 - 102.
- 25) Taniguchi H, Toyoshima T, Fukao K, Nakauchi H. Presence of hematopoietic stem cells in the adult liver. *Nature Medicine* 1996, 2(2); 198 – 203.
- 26) Mechal WZ, Azzaroli F, Crispe IN. Immunology of the healthy liver. *Gastroenterology* 2001, 120; 250 - 260.
- 27) Itoh T, Okanoue M, Morimoto Y, Nagao T, Mori N, Hori K, Kashima K. Functional heterogeneity of rat liver macrophages: interleukin-1 secretion and 1A antigen expression in contrast with phagocytic activity. *Liver* 1992, 12 (1); 26 -33
- 28) Mustafa SB, Olson MS. Expression of nitric-oxide synthase in rat kupffer cells is regulated by cAMP. *Journal of Biological Chemistry* 1998, 273(9); 5073 – 5080.
- 29) Takahashi M, Ogasawara K, Takeda K, Hashimoto W, Sakihara H. LPS induces NK I+ alpha beta T cells with potent cytotoxicity in the liver of mice via production of IL- 12 from kupffer cells. *Journal of Immunology* 1996, 156(7); 2436 – 2442.
- 30) Kamimura S, Tsukamoto, H. (1995). Cytokine gene expression by kupffer cells. *Hepatology* 1995, 22(4); 1304 -1309. Thornton AJ, Ham J, Kunkel SL. Kupffer cell-derived cytokines induce the synthesis of a leukocyte chemotactic peptide, interleukin-8, in human hepatoma and primary hepatocyte. *Hepatology* 1991, 14(6); 1112 – 1122
- 31) Thornton AJ, Ham J, Kunkel SL. Kupffer cell-derived cytokines induce the synthesis of a leukocyte chemotactic peptide, interleukin-8, in human hepatoma and primary hepatocyte. *Hepatology* 1991, 14(6): 1112 - 1122
- 32) Erhardt A, Biburger M, Papadopoulos T, Tiegs G. IL-10, regulatory T cells, and kupffer cells mediate tolerance in concanavalin A- induced liver injury in mice. *Hepatology* 2007, 45(2); 475 - 485.
- 33) Schumann J, Wolf D, Pahl A, Brune K, Papadopoulos T, Van Rooijen N, Tiegs, G. Importance of kupffer cells for T-cells dependent liver injury in mice. *American Journal of Pathology* 2000. 157(5); 1671 – 1683.

- 
- 34) Bowen DG, Warren A, Davis T. Cytokine- dependent hepatitis due to intrahepatic murine CD8 Tcell activation by bone marrow derived cells. *Gastroentology* 2002, 123(4); 1252 - 1264.
  - 35) Yoshimoto T, Paul, WE. CD4 POS promptly produce interleukin-4 in response to in vivo challenge with anti-CD3. *Journal of Experimental Medicine* 1994, 179(4); 1285 -1295.
  - 36) Burdin N, Brossay L, Koezuka Y, Smiley ST, Grusby MJ, Gui M. Selective ability of mouse CD1 to present glycolipids: alpha-galactosylceramides specifically stimulates S V alpha 14+ NKT lymphocytes. *Journal of Immunology* 1998, 161(7); 3271 - 3281.
  - 37) Geissmann F, Cameron TO, Sidobre S, Manlongat N, Kronenberg M. Intravascular immune surveillance by cells patrolling liver sinusoids. *Plos Biology* 2005, 3(4); 113 - 120.
  - 38) Bowen DG, McCaughan GW, Bertolino P. Intrahepatic immunity: a tale of two sites. *Trends in Immunology* 2005, 26(10); 512 – 517.
  - 39) Albano E, French SW, Ingleman-Sundberg M. Hydroxyethyl radicals in ethanol hepatotoxicity. *Frontiers in Bioscience* 1999, 4, 533 – 540.
  - 40) C.Weiler-Normann, J. Herkel, A.W. Lohse. Mouse Models of Liver Fibrosis. 10.1055/s-2006-927387 *Z Gastroenterol* 2007; 45: 43–50.
  - 41) Arthur MJ., Collagenases and liver fibrosis. *J Hepatol* 1995; 22: 43-48
  - 42) Friedman SL. Seminars in medicine of the Beth Israel Hospital, Boston. The cellular basis of hepatic fibrosis. Mechanisms and treatment strategies. *N Engl J Med* 1993; 328; 1828-1835
  - 43) Knittel T, Kobold D, Piscaglia F et al. Localization of livermyofibroblasts and hepatic stellate cells in normal and diseased rat livers: distinct roles of (myo-)fibroblast subpopulations in hepatic tissue repair. *Histochem Cell Biol* 1999; 112: 387-401
  - 44) Knittel T, Kobold D, Saile B et al. Rat liver myofibroblasts and hepatic stellate cells: different cell populations of the fibroblast lineage with fibrogenic potential. *Gastroenterology* 1999; 117: 1205-122.

- 
- 45) Mitaka T, Sato F, Mizuguchi T et al. Reconstruction of hepatic organoid by rat small hepatocytes and hepatic nonparenchymal cells. *Hepatology* 1999; 29; 111-125
  - 46) Be'ne'dicte Delire<sup>1</sup>, Peter Sta'rkell<sup>1,2</sup> and Isabelle Leclercq. Animal Models for Fibrotic Liver Diseases: What We Have, What We Need, and What Is under Development *Journal of Clinical and Translational Hepatology* 2015. vol. 3 ; 53-66
  - 47) Lee UE, Friedman SL. Mechanisms of hepatic fibrogenesis. *Best Pract Res Clin Gastroenterol* 2011;25:195–206. doi: 10.1016/j.bpg.2011.02.005
  - 48) Bedossa P, Paradis V. Liver extracellular matrix in health and disease. *J Pathol* 2003; 200: 504-515
  - 49) Lalazar A, Wong L, Yamasaki G et al. Early genes induced in hepatic stellate cells during wound healing. *Gene* 1997; 195: 235-243
  - 50) Eng FJ, Friedman SL. Fibrogenesis I. New insights into hepatic stellate cell activation: the simple becomes complex. *Am J Physiol Gastrointest Liver Physiol* 2000; 279: G—G11
  - 51) Ramadori G, Veit T, Schwogler S et al. Expression of the gene of the alpha-smooth muscle-actin isoform in rat liver and in rat fat-storing (ITO) cells. *Virchows Arch B Cell Pathol Incl Mol Pathol* 1990; 59: 349-357
  - 52) Knittel T, Schuppan D, Meyer zum Buschenfelde KH et al. Differential expression of collagen types I, III, and IV by fat-storing (Ito) cells in vitro. *Gastroenterology* 1992; 102: 1724-1735
  - 53) Ramadori G, Rieder H, Knittel T et al. Fat storing cells (FSC) of rat liver synthesize and secrete fibronectin. Comparison with hepatocytes. *J Hepatol* 1987; 4: 190-197
  - 54) Olaso E, Friedman SL. Molecular regulation of hepatic fibrogenesis. *J Hepatol* 1998; 29: 836-847
  - 55) Blobe GC, Schiemann WP, Lodish HF. Role of transforming growth factor beta in human disease. *N Engl J Med* 2000; 342: 1350-1358
  - 56) Zhou S, Kinzler KW, Vogelstein B. Going mad with Smads. *N Engl J Med* 1999; 341: 1144-1146.

- 
- 57) Knittel T, Mehde M, Kobold D et al. Expression patterns of matrix metalloproteinases and their inhibitors in parenchymal and non-parenchymal cells of rat liver: regulation by TNF-alpha and TGF-beta1. *J Hepatol* 1999; 30: 48-60.
  - 58) Arthur MJ, Mann DA, Iredale JP. Tissue inhibitors of metalloproteinases, hepatic stellate cells and liver fibrosis. *J Gastroenterol Hepatol* 1998; 13 (Suppl): S33-S38.
  - 59) Iredale JP, Benyon RC, Arthur MJ et al. Tissue inhibitor of metalloproteinase- 1 messenger RNA expression is enhanced relative to interstitial collagenase messenger RNA in experimental liver injury and fibrosis. *Hepatology* 1996; 24: 176-184.
  - 60) American Liver Foundation (ALF), Hepatitis Foundation International, United Network for Organ Sharing and National Digestive Diseases Information Clearinghouse Cirrhosis of Liver Information Sheet Ver3.0 – July 2013.
  - 61) Dr. Sandip Mali, Pitambari Innovation Product Pvt. Ltd. Preparation of stable Gomutra Formulation ‘ Gomutra Plus w. r. t. Conventional form of Gomutra; 4-6
  - 62) Gulhane Harshad, Nakanekar Amit, Mahakal Nilesh, Bhople Sunanda, Salunke Amrut Gomutra Cow Urine : A multidimensional drug review article 2017 10.7897/2277-4343.085231
  - 63) Valiathan M. S. Hyderabad, India, Orient Longman Private Ltd, 2007, The Legacy Of Susruta, Page no. 158
  - 64) Dhama K, Chauvhan R. S., Singhal Lokesh. Anti-Cancer Activity Of Cow Urine: Current Status and Future Directions, *International Journal Of Cow Science*, 1(2):1-25 2005
  - 65) Jain NK, Gupta VB, Garg Rajesh, Silwat N. Efficacy of cow urine therapy on various cancer patients, 2010, Vol-1, Issue-4, Page no. 29-35.
  - 66) Dhama K, Chakraborty S, Mahima, YakoobWani M 2013. Novel and emerging therapies safeguarding health of human and their companion animals : A Review. *Pak. J. Bio. Sci.* 16(3): 101-113 .
  - 67) Pathak ML, Kumar A. Cow praising and importance of Panchyagavya as medicine. *Sachitra Ayurveda* 2003;5:569.



- 
- 68) Randhawa GK. Cow urine distillate as bioenhancer. J Ayurveda Integr Med 2010; 1:240-1
- 69) urinetherapy.in homepage on internet (cited 2017 april 19) Available from - <http://www.urinetherapy.in/ancientreference.aspx>
- 70) quora.com homepage on internet Is-gomutra-cows-urine-a-good-medicine-for-diabetes-and-obesity (cited- 2017 April 19) Available from - <https://www.quora.com/Is-gomutra-cows-urine-a-good-medicine-for-diabetes-and-obesity>
- 71) Charaka, charaka Samhita, with Ayurveda-DipikasAyusi Hindi-commentary edited by Kushavaha Harish Chandra Singh, sutrasthana, chapter 1, verse 111, Published by Chaukhambha Sanskrit Pratishthan, Delhi 2011
- 72) Sushruta, Sushrut Samhita edited by Sharma Anantaram, Sutrasasthana, Chapter 45, verse 217, Published Chaukhambha Surbharati Prakashan, Varanasi 2009
- 73) Ayurveda Sarsamgraha, shri Baidyanath Ayurved Bhavan private Ltd, Nagpur,2004.
- 74) samvadsetu-gaumata.home page on internet (cited 2017 April 19) Available from- <http://samvadsetu-gaumata.blogspot.in/2010/12/cow-urine-content.html>
- 75) Dhama K, Chauvhan R. S., Singhal Lokesh. Anti-Cancer Activity of Cow Urine: Current Status and Future Directions, International Journal Of Cow Science, 1(2):1-25 2005
- 76) Ganguly S, Prasad A. Role of plant extracts and cow urine distillate as, immunomodulator in comparison to Levamisole - A Review, Journal of Immunology and Immunopathology, Vol.12, No.2, July-December 2010: 91-94.
- 77) Gosavi D. D. Sachadev D. Salwe K, 2011 Immunomodulator and Antioxident effect of GomutraArka in RatsJ MGIMS, September 2011, Vol 16, No (ii), 37-41.
- 78) Randhawa Gurpreet k. Sharma R, Chemotherapeutic potential of cow urine: A review,Journal of Intercultural Ethnopharmacology, 2015 Apr-Jun,Vol-4,issue-2,180-186.
- 79) Rajapandiyam K, Shanthi S, Murugan AM, Muthu GA, Singh AJ. Azadirachta indica - Cow urine extract, a novel controlling agent towards clinically significant multi drug resistant pathogens. J Appl Pharm Sci 2011;1:107-13.].
-

- 
- 80) Kumar S. Analysis on the natural remedies to cure dandruff/skin disease-causing fungus - *Malassezia furfur*. *AdvBioTech* 2013;12:1-5.
  - 81) Kekuda PT, Nishanth BC, Kumar PS, Kamal D, Sandeep M, Megharaj HK. Cow urine concentration: A potent agent with antimicrobial and anthelmintic activity. *J Pharm Res* 2010;3:1025-7.
  - 82) Randhawa Gurpreet k. Sharma R, Chemotherapeutic potential of cow urine: A review, *Journal of Intercultural Ethnopharmacology*, 2015 Apr-Jun, Vol-4, issue-2, 180-186.
  - 83) Kekuda PT, Nishanth BC, Kumar PS, Kamal D, Sandeep M, Megharaj HK. Cow urine concentration: A potent agent with antimicrobial and anthelmintic activity. *J Pharm Res* 2010;3:1025-7.
  - 84) Randhawa GK. Cow urine distillate as bioenhancer. *J Ayurveda Integr Med* 2010;1:240-1.
  - 85) Kekuda PT, Nishanth BC, Kumar PS, Kamal D, Sandeep M, Megharaj HK. Cow urine concentration: A potent agent with antimicrobial and anthelmintic activity. *J Pharm Res* 2010;3:1025-7.
  - 86) Chauhan RS, Singhal L. Harmful effects of Pesticides and their control through cowpathy. *Int J Cow Sci* 2006;2:61-70.].
  - 87) Khanuja SP, Kumar S, Shasany AK, Arya JS, Darokar MP. Use of bioactive fraction from cow urine distillate ('Go-mutra') as a bioenhancer of anti-infective, anti-cancer agents and nutrients. US Patent US 7235262; 2007.
  - 88) Kumar A, Kumar P, Singh LK, Agrawal DK. Pathogenic effects of free radicals and their prevention through cowpathy. *Indian Cow* 2004;6:27-34.].
  - 89) Raja W, Agrawal RC. Chemopreventive potential of cow urine against 7, 12 dimethyl benz(a) anthracene-induced skin papillomasgenesis in mice. *Acad J Cancer Res* 2010;3(1):7-10.
  - 90) Jain NK, Gupta VB, Garg R, Silawat N. Efficacy of cow urine therapy on various cancer patients in Mandsaur District, India -A survey. *Int J Green Pharm* 2010;4:29-35.].
  - 91) Chauhan RS, Singh BP, Singhal LK. Immunomodulation with Kamdhenu ark in mice. *J ImmunolImmunopathol* 2001;3:74-7.].

- 92) Hiren N. Hirapara, Vishal M. Ghori, Ashish P. Anovadiya, Chandrabhanu R. Tripathi. Evaluation of wound healing activity of cow urine ark in diabetic Wistar albino rats, *Journal of intercultural Ethnopharmacology*, 2016 vol-5 Issue-4, 434-438
- 93) Jarald E, Edwin S, Tiwari V, Garg R, Toppo E. Antioxidant and antimicrobial activities of cow urine. *Glob J Pharmacol* 2008;2:20-2.
- 94) Upadhyay RK, Dwivedi P, Ahmad S. Antimicrobial activity of photoactivated cow urine against certain pathogenic bacterial strains. *Afr J Biotechnol* 2010;9:518-22.].
- 95) Singh UP, Maurya S, Singh A, Nath G, Singh M. Antimicrobial efficacy, disease inhibition and phenolic acid-inducing potential of chloroform fraction of cow urine. *Arch Phytopathol Plant Protect* 2012;45:1546-57.
- 96) Kumar S. Analysis of cow's urine for detection of lipase activity and antimicrobial properties. *J Pharm BiolSci* 2013;7:1-8.
- 97) Hor-Yue Tan, Serban San-Marina, Ning Wang, Ming Hong, Sha Li, Lei Li, Fan Cheung, Xiao-YanWen, and Yibin Feng. Preclinical Models for Investigation of Herbal Medicines in liver Diseases: Update and Perspective. Volume 2016, Article ID 4750163.
- 98) Z. Zhao, H. Yu, Y. Peng et al., "Comparison of effect of formulas clearing away heat and promoting blood circulation on prevention and treatment of liver fibrosis in CCl4 mice," *Zhongguo Zhong Yao Za Zhi*, vol. 37, no. 12, 2012 pp. 1804–1808.
- 99) C. Luo, Z.-X. Chen, X.-H. Tan et al., "Therapeutic effects of Fuzhenghuayu decoction in a CCl4-induced liver cirrhosis rat model and on hepatic stellate cell activation," *Zhonghua Gan Zang Bing Za Zhi*, vol. 21, no. 9, 2013, pp. 668–673.
- 100) L. J. Zhang, M. Y. Sun, B. B. Ning et al., "Xiayuxue decoction ([symbols; see text]) attenuates hepatic stellate cell activation and sinusoidal endothelium defenestration in CCl4-induced fibrotic liver of mice," *Chinese Journal of Integrative Medicine*, vol. 20, no. 7, 2014, pp. 516–523.
- 101) X. Shen, S. Cheng, Y. Peng, H. Song, and H. Li, "Attenuation of early liver fibrosis by herbal compound 'Diwu Yanggan' through modulating the balance

- between epithelial-to-mesenchymal transition and mesenchymal-to-epithelial transition,” *BMC Complementary and Alternative Medicine*, vol. 14, 2014, article 41,.
- 102) Y.-N. Zhou, M.-Y. Sun, Y.-P. Mu et al., “Xuefuzhuyu decoction inhibition of angiogenesis attenuates liver fibrosis induced by CCl<sub>4</sub> in mice,” *Journal of Ethnopharmacology*, vol. 153, no. 3, 2014, pp. 659–666.
- 103) X.-X. Wu, L.-M. Wu, J.-J. Fan et al., “Cortex Dictamni extract induces apoptosis of activated hepatic stellate cells via STAT1 and attenuates liver fibrosis in mice,” *Journal of Ethnopharmacology*, vol. 135, no. 1, 2011, pp. 173–178.
- 104) H. Qiao, H. Han, D. Hong, Z. Ren, Y. Chen, and C. Zhou, “Protective effects of baicalin on carbon tetrachloride induced liver injury by activating PPAR $\gamma$  and inhibiting TGF $\beta$ 1,” *Pharmaceutical Biology*, vol. 49, no. 1, 2011, pp. 38–45.
- 105) Y. Feng, N. Wang, X. Ye et al., “Hepatoprotective effect and its possible mechanism of Coptidis rhizoma aqueous extract on carbon tetrachloride-induced chronic liver hepatotoxicity in rats,” *Journal of Ethnopharmacology*, vol. 138, no. 3, 2011, pp. 683–690.
- 106) G.-Y. Li, H.-Y. Gao, J. Huang, J. Lu, J.-K. Gu, and J.-H. Wang, “Hepatoprotective effect of Cichorium intybus L., a traditional Uighur medicine, against carbon tetrachloride-induced hepatic fibrosis in rats,” *World Journal of Gastroenterology*, vol. 20, no. 16, 2014, pp. 4753–4760.
- 107) X.-P. Tian, Y.-Y. Yin, and X. Li, “Effects and mechanisms of acremoniumterricola milleret al mycelium on liver fibrosis induced by carbon tetrachloride in rats,” *The American Journal of Chinese Medicine*, vol. 39, no. 3, 2011, pp. 537–550.
- 108) Z.-C. Wang, S. Yang, J.-J. Huang, S.-L. Chen, Q.-Q. Li, and Y. Li, “Effect of Rougan Huaqian granules combined with human mesenchymal stem cell transplantation on liver fibrosis in cirrhosis rats,” *Asian Pacific Journal of Tropical Medicine*, vol. 7, no. 7, 2011, pp. 576–581.
- 109) F.-R. Yang, B.-W. Fang, and J.-S. Lou, “Effects of Fufang Biejia Ruangan Pills on hepatic fibrosis in vivo and in vitro,” *World Journal of Gastroenterology*, vol. 19, no. 32, 2013, pp. 5326–5333.

- 
- 110) C. Zhang, Y. Wang, H. Chen et al., "Protective effect of the herbal medicine Ganfukang against carbon tetrachloride induced liver fibrosis in rats," *Molecular Medicine Reports*, vol. 8, no. 3, 2013, pp. 954–962.
- 111) W. Li, Y. Wu, C. Zhu, Z. Wang, R. Gao, and Q. Wu, "Anti-fibrosis effects of Huisheng oral solution in CCl<sub>4</sub>-induced hepatic fibrosis in rat," *Indian Journal of Pharmacology*, vol. 46, no. 2, 2014, pp. 216–221.
- 112) A. N. B. Singab, N. A. Ayoub, E. N. Ali, and N. M. Mostafa, "Antioxidant and hepatoprotective activities of Egyptian moraceous plants against carbon tetrachloride-induced oxidative stress and liver damage in rats," *Pharmaceutical Biology*, vol. 48, no. 11, 2010, pp. 1255–1264.
- 113) H. B. Cai, X. G. Sun, Z. F. Liu et al., "Effects of dahuangzhechong pills on cytokines and mitogen activated protein kinase activation in rats with hepatic fibrosis," *Journal of Ethnopharmacology*, vol. 132, no. 1, 2010, pp. 157–164.
- 114) J.-X. Du, P. Liu, M.-Y. Sun et al., "Chinese herbal medicine Xiayuxue Decoction inhibits liver angiogenesis in rats with carbon tetrachloride-induced liver fibrosis," *Zhong Xi Yi Jie He Xue Bao*, vol. 9, no. 8, 2011, pp. 878–887.
- 115) D.-Z. Shen, Q. Tao, J.-X. Du et al., "Effects of Yiguanjian Decoction on liver cirrhosis formation a differential proteomics study in rats," *Zhong Xi Yi Jie He Xue Bao*, vol. 8, no. 2, 2010, pp. 158–167.
- 116) J.-C. Shu, L.-X. Chen, L. Deng et al., "Preliminary study on mechanism of therapeutic effect of Huguangjiexian decoction on hepatic fibrosis," *Zhonghua Gan Zang Bing Za Zhi*, vol. 18, no. 3, 2010, pp. 189–193.
- 117) Y.-P. Mu, X.-R. Chen, and Y.-F. Lu, "Effect of Xiaozheng Rongmu powder for the treatment of liver cirrhosis in rats," *Zhongguo Zhong Xi Yi Jie He Za Zhi*, vol. 30, no. 10, 2010, pp. 1078–1083.
- 118) P. Vinoth Kumar<sup>1</sup>, A. Sivaraj<sup>1</sup>, Ek. Elumalai<sup>2</sup>, B. Senthil Kumar<sup>1</sup>, Carbon Tetrachloride-Induced Hepatotoxicity in rats - protective role of aqueous leaf Extracts Of *Coccinia Grandis*. *International Journal Of Pharmtech Research* Vol.1, No.4, Pp 1612-1615, Oct-Dec 2009 Coden (Usa): Ijprif Issn : 0974-4304.
-

- 
- 119) Somasundaram, A, Sivashanmugam, T, Subhadradevi, V, Ravi, TK. Xanthine oxidase inhibitory activity of some Indian medical plants. *J Ethnopharmacol.* 2007;109:547-551.
  - 120) Bergmeyer, H, Bernt, E, In; Varley, H, Gowenlock, AH, Bell, M. *Practical Clinical Biochemistry*, 5th Edn., William Heinmann Medical Books Ltd, London 1980. pp 741.
  - 121) King, EJ, Amstrong, AR, *Method of King and Amstrong* In; Varley, H, Gowenlock, AH, Bell, M. *Practical Clinical Biochemistry*, 5th Edn., William Heinmann Medical Books Ltd, London 1980; 897.
  - 122) Devendra O. Sachdev, Devesh D. Gosavi, and Kartik J. Salwe, Evaluation of Antidaibetic , antioxidant effect and safety profile of gomutra ark in Wistar albino rats, 2012 Jan-Mar; 31(3); pp 84-89.
  - 123) Truechemie SGOT (AST) test kit (IFCC) for the quantitative determination of serum Glutamate oxaloacetate transaminase (SGOT) in human serumor plasma. Page1 of 1; 12.05.2016.
  - 124) Truechemie SGPT (ALT) test kit (IFCC) for the quantitative determination of serum Glutamate pyruvate transaminase (SGPT) in human serumor plasma. Page1 of 1; 12.05.2016.
  - 125) Truechemie ALP (ALKALINE PHOPHATASE) single reagent test kit (IFCC) for the quantitative determination of serum of alkaline phosphatase concentration in serum of plasma. Page1 of 1; 12.05.2016.

## List of abbreviations

NK T-cell	Natural Killer T-Cell
KC	Kupffer Cell
TGF	Transforming growth factor
ATP	Adenosine Triphosphate
LP	Lipolysachharide
IL	Interlukins
TNF	Tumor Necrosis Factor
TGF	Transforming growth factor
IFN	Interferon
HSC	Hematopoietic stem cell
ECM	Extracellular matrix
SMA	Spinal muscular atrophy
NASH	Nonalcoholic fatty liver disease
CAT	Computerized axial tomography scan
MCF	Medical Care facility
i.p.	Intra-peritoneal
C.U.	Cow urine
MIC	Minimum inhibitory concentration
MDR	Multidrug resistance
CUC	Cow urine concentrate
CUD	Cow urine distillate
DNA	Deoxyribose nuclic acid
Ph CU	Photoactive Cow Urine
ALT	Alanine aminotransferase
ALP	Alkaline phosphatase
AST	Aspartate aminotransferase
BMP	Bitmap
TIMP	Tissue inhibitor of metalloproteinase
VEGF	Vascular endothelial growth factor
HIF	Hypoxia inducible factor
ADMA	Asymmetric dimethylarginine
CCl <sub>4</sub>	Carbon tetrachloride
CCl <sub>3</sub>	Car
CPCSEA	Committee for pourpose of control and supervision of Experimental on Animals
IAEC	Institutional Animal Ethics Committee
GoA	gomutra ark
ml/kg	Mililitre/kilogram
Mg/kg	Milligram/kilogram

### List of abbreviations

---

SEM	Standard error
Wt	Weight
LD <sub>50</sub>	Lethal dose
Conc.	Concentration
WHO	World health organization
Std	Standard
s	Second



## List of abbreviations

NK T-cell	Natural Killer T-Cell
KC	Kupffer Cell
TGF	Transforming growth factor
ATP	Adenosine Triphosphate
LP	Lipolysachharide
IL	Interlukins
TNF	Tumor Necrosis Factor
TGF	Transforming growth factor
IFN	Interferon
HSC	Hematopoietic stem cell
ECM	Extracellular matrix
SMA	Spinal muscular atrophy
NASH	Nonalcoholic fatty liver disease
CAT	Computerized axial tomography scan
MCF	Medical Care facility
i.p.	Intra-peritoneal
C.U.	Cow urine
MIC	Minimum inhibitory concentration
MDR	Multidrug resistance
CUC	Cow urine concentrate
CUD	Cow urine distillate
DNA	Deoxyribose nuclic acid
Ph CU	Photoactive Cow Urine
ALT	Alanine aminotransferase
ALP	Alkaline phosphatase
AST	Aspartate aminotransferase
BMP	Bitmap
TIMP	Tissue inhibitor of metalloproteinase
VEGF	Vascular endothelial growth factor
HIF	Hypoxia inducible factor
ADMA	Asymmetric dimethylarginine
CCl <sub>4</sub>	Carbon tetrachloride
CCl <sub>3</sub>	Car
CPCSEA	Committee for pourpose of control and supervision of Experimental on Animals
IAEC	Institutional Animal Ethics Committee
GoA	gomutra ark
ml/kg	Mililitre/kilogram
Mg/kg	Milligram/kilogram

### List of abbreviations

---

SEM	Standard error
Wt	Weight
LD <sub>50</sub>	Lethal dose
Conc.	Concentration
WHO	World health organization
Std	Standard
s	Second